

# Bronchiolitis Obliterans Organizing Pneumonia

Gary R. Epler, MD

**B**ronchiolar disorders can be divided into 2 general categories: (1) airway disorders (cellular bronchiolitis and obliterative bronchiolitis) and (2) parenchymal disorders (respiratory bronchiolitis–interstitial lung disease, which occurs in smokers and is treatable with smoking cessation or corticosteroid therapy, and bronchiolitis obliterans organizing pneumonia, an inflammatory lung disease simultaneously involving the terminal bronchioles and alveoli). This article reviews the clinical findings and therapeutic management of bronchiolitis obliterans organizing pneumonia.

*Arch Intern Med.* 2001;161:158-164

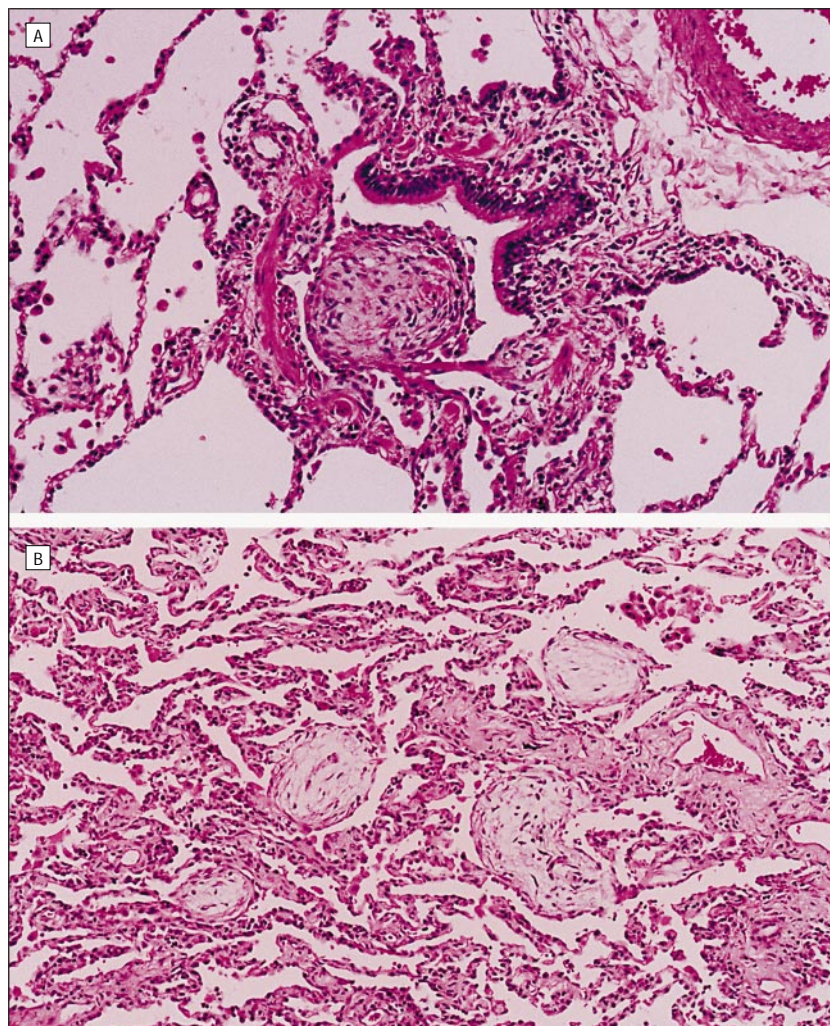
Bronchiolitis obliterans organizing pneumonia (BOOP) was described in 1985<sup>1</sup> as a distinct entity, with different clinical, radiographic, and prognostic features than the airway disorder obliterative bronchiolitis<sup>2</sup> and the interstitial fibrotic lung disorder usual interstitial pneumonia/idiopathic pulmonary fibrosis (UIP/IPF).<sup>3</sup> BOOP is characterized by polyploid endobronchial connective tissue masses composed of myxoid fibroblastic tissue resembling granulation tissue filling the lumens of terminal and respiratory bronchioles and extending in a continuous fashion into alveolar ducts and alveoli, representing an organizing pneumonia (**Figure 1**).<sup>1-3</sup> Other histological features include central clusters of mononuclear inflammatory cells possibly found in the intraluminal polyps (the polyps appear to float freely within a bronchiole or are focally attached to the wall), chronic inflammation in the walls of the surrounding alveoli with reactive type II cells, increased foamy macrophages in the alveoli, and preserved lung architecture.<sup>2</sup>

BOOP continues to be reported throughout the world.<sup>4-7</sup> Most patients have idiopathic BOOP, but there are several known causes of BOOP, and several systemic disorders have BOOP as an associated primary pulmonary lesion (**Table**).

The BOOP pattern might also occur as a secondary process in several clinical settings, such as the inflammatory-appearing lesion of UIP/IPF, with Wegener granulomatosis, in the walls of lung abscesses, around lymphoma or other neoplasms, and with bronchiectasis. In these patients, the underlying process is the primary cause of symptoms and the subsequent clinical course.

The terms *organizing pneumonia* and *cryptogenic organizing pneumonia* are sometimes used for the broad category of patients with organizing pneumonia. There are several reasons that the term *BOOP* should continue to be used for the clinical disorder and corresponding pathological lesion described in this review. First, investigators and clinicians throughout the world recognize the clinical and pathological features of this disorder, and they commonly use the term BOOP. Second, BOOP is a histological process that involves distal airways and alveoli simultaneously. Although various lung diseases represent a chronic inflammatory process, it is now apparent that the processes differ markedly among various diseases, such as chronic obstructive pulmonary disease, asthma, and BOOP, with different inflammatory cells, mediators, inflammatory effects, and response to treatment.<sup>8</sup> Therefore, an inflammatory lesion that involves only airways or only alveoli may have different in-

From Harvard Medical School, Pulmonary and Critical Care Medicine, Brigham and Women's Hospital, Boston, Mass.



**Figure 1.** A, Intraluminal organization and polypoid granulation tissue within a small bronchiole. B, Organization and polypoid granulation tissue within small bronchioles, alveolar ducts, and alveoli. The associated alveolar walls show type II cell metaplasia and mild inflammatory thickening. Courtesy of Thomas V. Colby, MD, Department of Pathology, Mayo Clinic Scottsdale (Ariz) (both parts).

flammatory components than the BOOP lesion that involves airway and alveoli simultaneously. Third, investigations of specific treatments for BOOP will be more strongly positive if the specific definition of BOOP is used for inclusion of patients rather than using the broad definition of organizing pneumonia. This is similar to IPF, in which many distinct histological disorders were included in this category in the past, resulting in dilution of the actual mechanism and poor treatment results. Now that IPF is limited to UIP,<sup>3</sup> the opportunity to fully characterize the fibrotic pathway is much greater, and antifibrotic treatment tailored to this fibrotic pathway will be tested more efficiently and accurately.

### PATHOGENESIS OF BOOP

BOOP is an inflammatory lung disease and thus is related to the inflammatory pathway rather than the fibrotic pathway that occurs with UIP/IPF. The inflammatory response associated with disorders such as asthma, chronic obstructive pulmonary disease, granulomatous diseases, and BOOP have common features of the sequential inflammatory response, yet these disorders seem to have differences that have not yet been fully characterized. These differences are important because treatment directed toward one type of inflammatory response might not be effective against another type.<sup>8</sup>

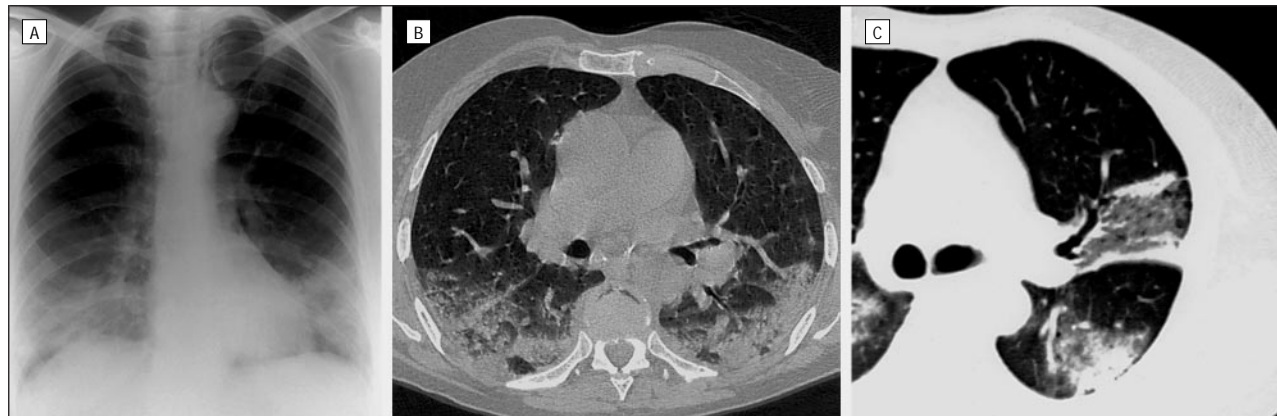
There is newly formed fibromyxoid connective tissue in BOOP

### Classification of BOOP\*

- Idiopathic BOOP
- Rapidly progressive BOOP
- Focal nodular BOOP
- Postinfection BOOP
  - Chlamydia*, *Legionella*, and *Mycoplasma*
  - Adenovirus, cytomegalovirus, and influenza virus
  - Malaria and *Pneumocystis*
  - Cryptococcus*
- Drug-related BOOP
  - Antibiotics: amphotericin B, cephalosporins, minocycline, nitrofurantoin, sulfasalazine, and sulfamethoxypyridazine
  - Bleomycin sulfate and methotrexate
  - Gold
  - Amiodarone
  - Illicit use of cocaine
  - L-tryptophan
  - Phenytoin
  - Carbamazepine
  - Ticlopidine hydrochloride
- Rheumatologic or connective tissue BOOP
  - Lupus erythematosus
  - Rheumatoid arthritis
  - Sjögren syndrome and Sweet syndrome
  - Polymyositis-dermatomyositis
  - Scleroderma—progressive systemic sclerosis
  - Ankylosing spondylitis
  - Polymyalgia rheumatica
  - Behçet syndrome
- Immunologic disorder BOOP
  - Common variable immunodeficiency syndrome
  - Essential mixed cryoglobulinemia
- Organ transplantation BOOP
  - Bone marrow, lung, and renal
- Radiotherapy BOOP
- Environmental exposures
  - Textile printing dye
  - Penicillium* mold dust
  - House fire
- Miscellaneous BOOP
  - Inflammatory bowel disease
  - Lymphoma and cancer
  - T-cell chronic lymphocytic leukemia
  - Human immunodeficiency virus infection
  - Myelodysplastic syndrome
  - Hunner interstitial cystitis
  - Chronic thyroiditis and alcoholic cirrhosis
  - Seasonal syndrome with cholestasis
  - Primary biliary cirrhosis
  - Coronary artery bypass graft surgery

\*BOOP indicates bronchiolitis obliterans organizing pneumonia.

and UIP/IPF; in BOOP it can be completely reversed by corticosteroid therapy, but in UIP/IPF this tissue participates in the remodeling and destruction of the interstitium.<sup>9,10</sup> Reasons for the response to corticosteroid in BOOP and the destruc-



**Figure 2.** A, Chest radiograph of a 54-year-old man with a flulike illness, bilateral crackles, decreased vital capacity, and a decreased diffusing capacity that shows bilateral patchy infiltrates in the lower lungs. B, High-resolution chest computed tomographic scan shows areas of patchy consolidation and ground glass opacities. Courtesy of Philip Costello, MD, and Andetta R. Hunsaker, MD, Department of Radiology, Brigham and Women's Hospital, Boston, Mass. C, Chest computed tomographic scan shows a triangular area of consolidation posteriorly.

tion in UIP/IPF remain unknown.<sup>11</sup> There seems to be abundant capillarization in the intra-airway fibromyxoid lesions in BOOP compared with minimal vascularization in UIP/IPF.<sup>9</sup> This might be because of vascular growth factors in BOOP that will result in normal apoptosis (natural-occurring cell death) in BOOP but not in UIP/IPF. Results of an additional study<sup>10</sup> showed that the apoptotic activity is higher in the fibromyxoid lesion of BOOP compared with UIP/IPF, suggesting that apoptosis has an important role in the resolution process of the newly formed connective tissue in BOOP.

### DIAGNOSING BOOP

Lung biopsy continues to be the preferred method for establishing a diagnosis. The video-assisted thoracoscopic procedure has become the established technique. In a study<sup>12</sup> of 49 patients who underwent the video-assisted thoracoscopic procedure for interstitial lung disease, the mean length of the operation was 45 minutes, the chest tube was inserted for 1.3 days, there were no deaths, there were no reexplorations, and none were converted to an open thoracotomy.

### RADIOGRAPHIC FINDINGS OF BOOP

The typical chest radiograph shows bilateral patchy (alveolar) infiltrates (**Figure 2A**). Cavities are rare, although 4 of 5 patients with a single pulmonary nodule had cavitation.<sup>13</sup> Effusions are rare. Linear

opacities occurring at the bases are usually associated with a poorer prognosis; however, a study<sup>6</sup> of BOOP in 23 patients in Korea indicated recovery in all patients regardless of their radiographic findings. Generally, the infiltrates gradually enlarge from their original site or new infiltrates appear as the clinical course progresses; however, migratory or "mobile" pulmonary infiltrates have been reported<sup>6,14,15</sup> in 10% to 25% of patients. Unilateral BOOP also has been reported.<sup>16,17</sup>

The chest computed tomographic scan shows findings similar to the chest radiograph, with bilateral areas of consolidation and ground glass opacities, usually with a peripheral location (Figure 2B). Costabel et al<sup>15</sup> reported that sometimes the peripheral opacities are in the form of triangles, with the base of the triangle along the pleural surface and the tip of the triangle toward the mediastinum (Figure 2C). In a study<sup>18</sup> from England, high-resolution chest computed tomographic scans showed 2 types of linear opacities: the first extends in a radial manner along the line of the bronchi toward the pleura and the second occurs in a subpleural location with no relation to the bronchi. Both types usually occur in the lower lobes, frequently associated with multifocal areas of consolidation, and usually completely resolve with treatment.

### TREATMENT OF BOOP

Prednisone, with its potent anti-inflammatory property, continues to

be recommend as first-line treatment for patients with symptomatic and progressive disease. Patients with asymptomatic mass lesions or non-progressive disease can be observed and treated at a later time if needed. The dosage is generally 1 mg/kg (60 mg/d) for 1 to 3 months, then 40 mg/d for 3 months, then 10 to 20 mg/d or every other day for a total of 1 year. Every-other-day scheduling can be successfully used for this disorder. A shorter 6-month course may be sufficient in certain situations. Total and permanent recovery is seen in most patients and is somewhat dependent on the cause or associated systemic disorders. Anecdotally, erythromycin, inhaled triamcinolone, and cyclophosphamide have been used to treat BOOP.<sup>19-21</sup> Epidemiological studies of these agents have not yet been performed for confirmation of efficacy.

### RECURRENCE OF BOOP

In patients treated for less than 1 year, BOOP might recur in one third. It is a lung disorder that can be successfully treated a second and third time with the previously responsive dosage level of prednisone.<sup>1</sup> Relapse of BOOP may be related to the severity of the illness. In a group of 7 patients who had a relapse it was found that the level of hypoxemia at the time of diagnosis was the most important determinant of relapse<sup>22</sup>; however, Cordier<sup>11</sup> did not find this relation.

For patients who do not respond to treatment, it is important

to determine if the BOOP pattern is primary or secondary. On close evaluation by a lung pathologist, the biopsy specimen that shows the BOOP pattern might also show the typical leading edge of "fibroblastic foci" that indicates UIP/IPF. The BOOP pattern might respond to corticosteroid therapy, yet the fibrotic process of UIP/IPF is the driving force of the progressively deteriorating clinical course.

## TYPES OF BOOP

Idiopathic BOOP is the most common type.<sup>1</sup> A flulike illness, fever, and an increased erythrocyte sedimentation rate continue to be typical findings of this form of BOOP. Cough and dyspnea are common but generally mild. Hemoptysis is uncommon, although it has been reported in 2 patients as a presenting symptom<sup>23</sup> and in some patients with nodules.<sup>13,24</sup> Crackles occur in two thirds of patients. Pneumothorax has occurred as a complication of BOOP in one patient with an effusion,<sup>25</sup> one with a solitary nodule,<sup>26</sup> and another with respiratory distress.<sup>27</sup> Results of pulmonary function studies show mildly to moderately decreased vital capacity. The flow rates are normal except in smokers. The diffusing capacity is decreased in almost all patients, although generally mildly to moderately. The prognosis of idiopathic BOOP remains good, some patients resolve without treatment, and 65% to 80% of patients treated with corticosteroid therapy are cured.

Rapidly progressive BOOP can occur in a small percentage of patients, but it is a deadly form of the disease.<sup>28,29</sup> In some of these patient reports, there was an underlying fibrotic process as the cause of the ultimate fatal course, with BOOP as a secondary component, yet some patients seemed to have a primary, rapidly developing BOOP, which had a better prognosis. This form of BOOP occurs equally in men and women and at all ages. It can occur in healthy, vigorous individuals or can be associated with other systemic disorders. The course can be rapid, with 1 to 3 days of symptoms and acute respiratory failure. Patients might present with adult respiratory distress syndrome, with

pathological findings indicating an organizing adult respiratory distress syndrome pattern with the appearance of BOOP.<sup>30</sup> Clinically, rapidly progressive BOOP can be indistinguishable from acute interstitial pneumonia.<sup>31,32</sup> Early histological diagnosis of the primary BOOP lesion and initiation of corticosteroid therapy might improve survival in these patients.<sup>29</sup>

Focal nodular BOOP was reported<sup>33</sup> in 1989 in 5 of 16 patients with idiopathic BOOP. Since then it has become a clinically important process, especially because it might be indistinguishable from carcinoma of the lung.<sup>13,26,34-36</sup> Although some focal nodular lesions might progress to the typical bilateral process of idiopathic BOOP, most do not, and resection results in a cure.

Multiple nodular lesions can also occur,<sup>34,35</sup> and most regress spontaneously. Of 12 patients with multiple large nodules or masses, all had complete resolution of their symptoms, 10 with no therapy and 2 after corticosteroid therapy.<sup>34</sup> In these patients, pleuritic chest pain was the most common presenting symptom, occurring in 50%. The number of masses varied from 2 to 8 (mean, 5). The authors concluded that BOOP should be considered when multiple large nodular lesions have chest computed tomographic findings showing air bronchograms, irregular margins, broad pleural tags, parenchymal bands, or subpleural lines.

Clinician investigators<sup>36</sup> in New Orleans suggest that BOOP may have a connection to reports of spontaneous regression of lung metastases. They concluded that a major reason that reports of spontaneous regression of lung metastasis have decreased in recent years is the increasing emphasis on obtaining diagnostic tissue of multiple nodular lesions for lung metastasis, many of which have proven to be BOOP.

Postinfection BOOP can develop after a variety of different types of infectious pneumonias,<sup>11</sup> including those caused by bacterial agents such as *Chlamydia*,<sup>37</sup> *Legionella*, and *Mycoplasma pneumoniae*<sup>38</sup> and viral agents such as parainfluenza virus<sup>16</sup> and adenovirus.<sup>39</sup> Parasitic infections such as malaria<sup>40</sup> and fungal in-

fections, including *Cryptococcus neoformans*<sup>41</sup> and *Pneumocystis carinii*,<sup>42</sup> have also been reported as a cause of the BOOP lesion.

Generally for these patients, there is initial improvement of the infectious pneumonia with use of appropriate antimicrobial agents, but after a few days, it becomes apparent that the symptoms and radiographic findings persist. The pneumonia process has now become organized into the BOOP lesion. Corticosteroid treatment at this point is almost always successful.

Drug-related BOOP has been reported<sup>11,15</sup> from use of several different types of medications, including anti-inflammatory and immunosuppressive agents such as bleomycin sulfate, gold, and methotrexate; antibiotics such as sulfasalazine, sulfamethoxypyridazine, cephalosporins, and amphotericin B; illicit use of cocaine; and a massive dose of L-tryptophan. Minocycline-associated BOOP has been reported<sup>43</sup> in a woman who was taking this medication for acne. Descriptions of amiodarone-related BOOP continue to be reported.<sup>44</sup> Phenytoin-related BOOP with rapid improvement after corticosteroid therapy has been reported.<sup>45</sup> There has been a report<sup>46</sup> of a woman who developed carbamazepine-induced lupus erythematosus and associated BOOP, both of which responded to corticosteroid therapy. There has been a report<sup>47</sup> of ticlopidine hydrochloride, an inhibitor of platelet aggregation, associated with BOOP that resolved after withdrawal of the agent. BOOP has now been added to the spectrum of pulmonary lesions associated with nitrofurantoin.<sup>48</sup>

Rheumatologic or connective tissue BOOP is clinically similar to the idiopathic form and has been reported<sup>49-57</sup> with all of the connective tissue diseases. BOOP represents the patchy infiltrative lesions seen in patients with lupus erythematosus, rheumatoid arthritis, Sjögren syndrome, and dermatomyositis. The process often responds to corticosteroid therapy, unlike the fibrotic process that may occur in these disorders.

There has been a report of a patient with BOOP associated with der-

matomyositis that was resistant to corticosteroid therapy; with initiation of cyclophosphamide therapy, there was improvement of pulmonary and cutaneous findings.<sup>52</sup> BOOP can also occur in patients with ankylosing spondylitis,<sup>53</sup> polymyalgia rheumatica,<sup>54,55</sup> and Behçet disease<sup>56</sup> and might be the first manifestation of a connective disorder.<sup>57</sup>

Immunologic disease BOOP has been reported with common variable immunodeficiency syndrome<sup>58</sup> and essential mixed cryoglobulinemia.<sup>59</sup>

Bone marrow transplantation BOOP has been described in patients who underwent allogeneic marrow transplantation. There has also been a report of BOOP in a patient who received a syngeneic bone marrow transplant from his twin brother.<sup>60</sup> There is an additional report of a patient who developed ulcerative colitis and BOOP 7 months after receiving a bone marrow transplant from his brother.<sup>61</sup> It was not clear whether the BOOP was associated with the ulcerative colitis or from another cause, such as a cytomegalovirus infection. Too few reports have been published to determine whether BOOP in these patients is an incidental finding or represents a complication of bone marrow transplantation.

Lung transplantation BOOP has been reported<sup>62,63</sup> in 10% to 28% of lung transplant recipients. The lesion generally occurs 1 to 10 months after transplantation and is usually associated with the acute rejection reaction. The process is reversible for most of these patients, especially if the underlying acute rejection is successfully treated. The BOOP lesion may occur before the onset of obliterative bronchiolitis,<sup>62</sup> and whether this is a risk factor for lung transplantation obliterative bronchiolitis has not been established, but it is prudent to treat the BOOP reactions aggressively in these patients. Cytomegalovirus pneumonia-associated BOOP has also been described<sup>63</sup> in lung transplant recipients and is generally responsive to corticosteroid therapy.

Renal transplantation BOOP has been described<sup>64</sup> in 1 patient 12 weeks after transplantation. A rapid recovery occurred after an increase of the daily dose of methylprednisolone.

Radiotherapy BOOP has become an important clinical disorder in patients receiving radiotherapy to the breast.<sup>65-68</sup> Symptoms might occur 1 to 12 months after completion of radiotherapy. Symptoms might be minimal, but most patients have fever, nonproductive cough, and mild shortness of breath. The chest radiograph shows peripheral patchy or alveolar infiltrates, often outside the radiation field.<sup>66</sup> One study<sup>68</sup> indicated that all 11 patients studied had spontaneous migration of infiltrates from the irradiated lung to the contralateral nonirradiated lung with no nodular or reticular lesions. There can be a dramatic improvement with corticosteroid therapy, but relapses may occur.<sup>66,67</sup> Some investigators<sup>66,68</sup> have suggested that radiotherapy may "prime" the development of BOOP. Bronchoalveolar lavage studies of these patients indicate an increase in lymphocytes, mast cells, CD3 cells, and CD8 cells and a decrease in CD4 cells and the CD4-CD8 ratio<sup>68</sup>; however, the underlying mechanism remains unknown.

Environment-related BOOP continues to be reported rarely. In 1992, textile printing dye-related BOOP was described in 22 textile airbrush workers.<sup>69</sup> Six died initially. Follow-up of some of the workers indicated gradual improvement over time.<sup>70</sup> It has been suggested<sup>69</sup> that the cause was related to the spraying of a respirable aerosol into the distal airways and alveoli; however, the reactive chemical agent and mechanism remain unclear. It is also not known whether the organizing pneumonia was a de novo process or resulted from the late organization of pulmonary edema.<sup>69</sup> *Penicillium* mold dust-related BOOP has been described<sup>71</sup> in a patient who developed BOOP after inhalation of powdery dust of a growth of *Penicillium janthinellum* mold on the top of a discarded orange juice container. Smoke inhalation BOOP has been reported<sup>72</sup> in a patient who was in a house fire and had erythema nodosum.

Miscellaneous BOOP continues to be reported, eg, in association with myelodysplastic syndrome,<sup>73</sup> Hunner interstitial cystitis,<sup>74</sup> chronic thyroiditis,<sup>75</sup> alcoholic cirrhosis,<sup>75</sup> and, in England, seasonal syndrome

with cholestasis.<sup>76</sup> It has been reported in patients with human immunodeficiency virus infection,<sup>77</sup> with one report during pregnancy.<sup>78</sup> Inflammatory bowel disease-related BOOP has been described<sup>79</sup> as an important treatable disorder in these patients. The BOOP lesion might be associated with lymphoma, and an atypical course of what is thought to be idiopathic BOOP may indicate a neoplastic process such as a lymphoma.<sup>80</sup> Recurrent BOOP responsive to prednisone treatment has been reported in T-cell leukemia.<sup>81,82</sup> BOOP has also been reported in primary biliary cirrhosis<sup>83</sup> and after coronary artery bypass graft surgery.<sup>84</sup>

## CONCLUSIONS

The busy clinician will see patients with a febrile illness and patchy infiltrates who have not responded to antibiotic drug therapy. The patient might have BOOP. Sometimes this disorder is treated in the hospital, but it is generally managed on an ambulatory basis. Typical idiopathic BOOP is characterized by a flulike illness, bilateral crackles, and patchy infiltrates and can be cured in 65% to 80% of patients with prednisone therapy. BOOP has become an important consideration in the diagnosis of focal nodular lesions. Postinfectious pneumonia BOOP remains a treatable process. BOOP occurs in virtually all of the connective tissue disorders and generally responds to corticosteroid therapy. It is an important treatable inflammatory lung disease.

Accepted for publication August 15, 2000.

Corresponding author and reprints: Gary R. Epler, MD, Pulmonary and Critical Care Medicine, Brigham and Women's Hospital, 75 Francis St, Boston, MA 02115 (e-mail: gepler@mediaone.net).

## REFERENCES

1. Epler GR, Colby TV, McLoud TC, Carrington CB, Gaensler EA. Bronchiolitis obliterans organizing pneumonia. *N Engl J Med*. 1985;312:152-158.
2. Colby TV. Bronchiolitis. *Am J Clin Pathol*. 1998; 109:101-109.
3. American Thoracic Society and European Respi-

- ratory Society. Idiopathic pulmonary fibrosis: diagnosis and treatment. *Am J Respir Crit Care Med*. 2000;161:646-664.
4. Cazzato S, Zompatori M, Baruzzi G, et al. Bronchiolitis obliterans-organizing pneumonia: an Italian experience. *Respir Med*. 2000;94:702-708.
  5. Lamont J, Verbeken E, Verschakelen J, Demedts M. Bronchiolitis obliterans organizing pneumonia: a report of 11 cases and a review of the literature. *Acta Clin Belg*. 1998;53:328-336.
  6. Han SK, Yim JJ, Lee JH, et al. Bronchiolitis obliterans organizing pneumonia in Korea. *Respirology*. 1998;3:187-191.
  7. Moreau L, Quoix E, Vandevenne A, et al. La bronchite oblitérante avec pneumopathie d'organisation: étude retrospective de 19 cas. *Rev Pneumol Clin*. 1998;54:136-143.
  8. Barnes PJ. Chronic obstructive pulmonary disease. *N Engl J Med*. 2000;343:269-280.
  9. Lappi-Blanco E, Kaarteenaho-Wilk R, Soini Y, Risteli J, Paakko P. Intraluminal fibromyxoid lesions in bronchiolitis obliterans organizing pneumonia are highly capillarized. *Hum Pathol*. 1999;30:1192-1196.
  10. Lappi-Blanco E, Soini Y, Paakko P. Apoptotic activity is increased in the newly formed fibromyxoid connective tissue in bronchiolitis obliterans organizing pneumonia. *Lung*. 1999;177:367-376.
  11. Cordier JF. Organising pneumonia. *Thorax*. 2000;55:318-328.
  12. Deshmukh SP, Krasna MJ, McLaughlin JS. Video assisted thoroscopic biopsy for interstitial lung disease. *Int Surg*. 1996;81:330-332.
  13. Murphy J, Schnyder P, Herold C, Flower C. Bronchiolitis obliterans organizing pneumonia simulating bronchial carcinoma. *Eur Radiol*. 1998;8:1165-1169.
  14. King TE. BOOP: an important cause of migratory pulmonary infiltrates? *Eur Respir J*. 1995;8:193-195.
  15. Costabel U, Guzman J, Teschler H. Bronchiolitis obliterans with organizing pneumonia: outcome. *Thorax*. 1995;50(suppl 1):S59-S64.
  16. Peramaki E, Salmi I, Kava T, Romppanen T, Hakkarainen T. Unilateral bronchiolitis obliterans organizing pneumonia and bronchoalveolar lavage neutrophilia in a patient with parainfluenza 3 virus infection. *Respir Med*. 1991;85:159-161.
  17. Kanwar BA, Shehan CJ, Campbell JC, Dewan N, O'Donohue WJ. A case of unilateral bronchiolitis obliterans organizing pneumonia. *Nebr Med J*. 1996;5:149-151.
  18. Murphy JM, Schnyder P, Verschakelen J, Leuenberger P, Flower CD. Linear opacities on HRCT in bronchiolitis obliterans organizing pneumonia. *Eur Radiol*. 1999;9:1813-1817.
  19. Ichikawa Y, Ninomyiyya H, Katsuki M, Hotta M, Tanaka M, Oizumi K. Low-dose long-term erythromycin for treatment of bronchiolitis obliterans organizing pneumonia (BOOP). *Kurume Med J*. 1993;40:65-67.
  20. Watson D, Fadem JJ. Bronchiolitis obliterans organizing pneumonia cured by standard dose inhaled triamcinolone. *South Med J*. 1995;88:980-983.
  21. Purcell IF, Bourke SJ, Marshall SM. Cyclophosphamide in severe steroid-resistant bronchiolitis obliterans organizing pneumonia. *Respir Med*. 1997;91:175-177.
  22. Watanabe K, Senju S, Wen F-Q, Shirakusa T, Maeda F, Yoshida M. Factors related to the relapse of bronchiolitis obliterans organizing pneumonia. *Chest*. 1998;114:1599-1606.
  23. Mroz BJ, Sexauer WP, Meade A, Balsara G. Hemoptysis as the presenting symptom in bronchiolitis obliterans organizing pneumonia. *Chest*. 1997;111:1775-1778.
  24. Froudarakis M, Bourros D, Loire R, Valasiadou K, Tsiftsis D, Siafakas NM. BOOP presenting with hemoptysis and multiple cavitary nodules. *Eur Respir J*. 1995;8:1972-1974.
  25. Kofteridis D, Bourros DE, Vamvakas LN, et al. Pneumothorax complicating fatal bronchiolitis obliterans organizing pneumonia. *Respiration*. 1999;66:266-268.
  26. Yang DG, Kim KD, Shin DH, Choe KO, Kim SK, Lee WY. Idiopathic bronchiolitis obliterans with organizing pneumonia presenting with spontaneous hydropneumothorax and solitary pulmonary nodule. *Respirology*. 1999;4:267-270.
  27. Iwanaga T, Hirota T, Ikeda T. Air leak syndrome as one of the manifestations of bronchiolitis obliterans organizing pneumonia. *Intern Med*. 2000;39:163-165.
  28. Cohen AJ, King TE, Downey GP. Rapidly progressive bronchiolitis obliterans with organizing pneumonia. *Am J Respir Crit Care Med*. 1994;149:1670-1675.
  29. Nizami IY, Kissner DG, Visscher DW, Dubaybo BA. Idiopathic bronchiolitis obliterans with organizing pneumonia: an acute and life-threatening syndrome. *Chest*. 1995;108:271-277.
  30. Perez de Llano LA, Soilan JL, Garcia Pais MJ, Mata I, Moreda M, Laserna B. Idiopathic bronchiolitis obliterans with organizing pneumonia presenting with adult respiratory distress syndrome. *Respir Med*. 1998;92:884-886.
  31. Ichikado K, Johkoh T, Ikezoe J, et al. A case of acute interstitial pneumonia indistinguishable from bronchiolitis obliterans organizing pneumonia. *Radiat Med*. 1998;16:367-370.
  32. Janz TG, Madan R, Marini JJ, et al. Clinical conference on management dilemmas: progressive infiltrate and respiratory failure. *Chest*. 2000;117:562-572.
  33. Cordier JF, Loire R, Brune J. Idiopathic bronchiolitis obliterans organizing pneumonia: definition of characteristic clinical profiles in a series of 16 patients. *Chest*. 1989;96:999-1004.
  34. Akira M, Yamamoto S, Sakatani M. Bronchiolitis obliterans organizing pneumonia manifesting as multiple large nodules or masses. *AJR Am J Roentgenol*. 1998;170:291-295.
  35. Orseck MJ, Player KC, Woollen CD, Kelley H, White PF. Bronchiolitis obliterans organizing pneumonia mimicking multiple pulmonary metastases. *Am Surg*. 2000;66:11-13.
  36. Chander K, Feldman L, Mahajan R. Spontaneous regression of lung metastases: possible BOOP connection [letter]? *Chest*. 1999;115:601-602.
  37. Diehl JL, Gisselbrecht M, Meyer G, Israel-Biet D, Sors H. Bronchiolitis obliterans organizing pneumonia associated with chlamydial infection. *Eur Respir J*. 1996;9:1320-1322.
  38. Llibre JM, Urban A, Garcia E, Carrasco MA, Murcia C. Bronchiolitis obliterans organizing pneumonia associated with acute *Mycoplasma pneumoniae* infection. *Clin Infect Dis*. 1997;25:1340-1342.
  39. Jeon JS, Yi HA, Ki SY, et al. A case of bronchiolitis obliterans organizing pneumonia associated with adenovirus. *Korean J Intern Med*. 1997;12:70-74.
  40. Yale SH, Adlakh A, Sebo TJ, Ryu JH. Bronchiolitis obliterans organizing pneumonia caused by *Plasmodium vivax* malaria. *Chest*. 1993;104:1294-1296.
  41. Carey CF, Mueller L, Fotopoulos CL, Dall L. Bronchiolitis obliterans-organizing pneumonia associated with *Cryptococcus neoformans* infection [letter]. *Rev Infect Dis*. 1991;13:1253-1254.
  42. Kleindienst R, Fend F, Prior C, Margreiter R, Vogel W. Bronchiolitis obliterans organizing pneumonia associated with *Pneumocystis carinii* infection in a liver transplant patient receiving tacrolimus. *Clin Transplant*. 1999;13:65-67.
  43. Piperno D, Donne C, Loire R, Cordier JF. Bronchiolitis obliterans organizing pneumonia associated with minocycline therapy: a possible cause. *Eur Respir J*. 1995;8:1018-1020.
  44. Conte SCS, Pagan V, Murer B. Bronchiolitis obliterans organizing pneumonia secondary to amiodarone. *Monaldi Arch Chest Dis*. 1997;52:24-26.
  45. Angle P, Thomas P, Chiu B, Freedman J. Bronchiolitis obliterans organizing pneumonia and cold agglutinin disease associated with phenytoin hypersensitivity syndrome. *Chest*. 1997;112:1697-1699.
  46. Milesi-Lecat AM, Schmidt J, Aumaitre O, Kemeny JL, Moinard J, Piette JC. Lupus and pulmonary nodule consistent with bronchiolitis obliterans organizing pneumonia induced by carbamazepine. *Mayo Clin Proc*. 1997;72:1145-1147.
  47. Alonso-Martinez JL, Elejalde-Guerra JI, Larrinaga-Linero D. Bronchiolitis obliterans organizing pneumonia caused by ticlopidine. *Ann Intern Med*. 1998;129:71-72.
  48. Cameron RJ, Kolbe J, Wilsher ML, Lambie N. Bronchiolitis obliterans organizing pneumonia associated with the use of nitrofurantoin. *Thorax*. 2000;55:249-251.
  49. Martinez FJ, Lynch JP. Connective tissue disease related bronchiolitis obliterans organizing pneumonia. In: Epler GR, ed. *Disease of the Bronchioles*. New York, NY: Raven Press; 1994:347-366.
  50. Ippolito JA, Palmer L, Spector S, Kane PB, Gorovic PD. Bronchiolitis obliterans organizing pneumonia and rheumatoid arthritis. *Semin Arthritis Rheum*. 1993;23:70-78.
  51. Imasaki T, Yoshi A, Tanaka S, Ogura T, Ishikawa A, Takahashi T. Polymyositis and Sjögren's syndrome associated with bronchiolitis obliterans organizing pneumonia. *Intern Med*. 1996;35:231-235.
  52. Knoell KA, Hook M, Grice DP, Hendrix JD. Dermatomyositis associated with bronchiolitis obliterans organizing pneumonia (BOOP). *J Am Acad Dermatol*. 1999;40:328-330.
  53. Turner JF, Enzenauer RJ. Bronchiolitis obliterans and organizing pneumonia associated with ankylosing spondylitis. *Arthritis Rheum*. 1994;37:1557-1559.
  54. Epler GR, Mark EJ. A 65-year-old woman with bilateral pulmonary infiltrates. *N Engl J Med*. 1986;314:1627-1635.
  55. Stey C, Truninger K, Marti D, Vogt P, Medici TC. Bronchiolitis obliterans organizing pneumonia associated with polymyalgia rheumatica. *Eur Respir J*. 1999;13:926-929.
  56. Gul A, Yilmazbayhan D, Buyukbabani N, et al. Organizing pneumonia associated with pulmonary artery aneurysms in Behçet's disease. *Rheumatology*. 1999;38:1285-1289.
  57. Fata F, Rathore R, Schiff C, Herzlich BC. Bronchiolitis obliterans organizing pneumonia as the first manifestation of polymyositis. *South Med J*. 1997;90:227-230.
  58. Kaufman J, Komorowski R. Bronchiolitis obliterans organizing pneumonia in common variable immunodeficiency syndrome. *Chest*. 1991;100:552-553.
  59. Zackrisson LH, Katz P. Bronchiolitis obliterans organizing pneumonia associated with essential

- mixed cryoglobulinemia. *Arthritis Rheum.* 1993;36:1627-1630.
60. Kanda Y, Takahashi T, Imai Y, et al. Bronchiolitis obliterans organizing pneumonia after syngeneic bone marrow transplantation for acute lymphoblastic leukemia. *Bone Marrow Transplant.* 1997;19:1251-1253.
  61. Baron FA, Hermanne JP, Dowlati A, et al. Bronchiolitis obliterans organizing pneumonia and ulcerative colitis after allogeneic bone marrow transplantation. *Bone Marrow Transplant.* 1998;21:951-954.
  62. Chaparro C, Chamberlain D, Maurer J, Winton T, Dehoyos A, Kesten S. Bronchiolitis obliterans organizing pneumonia (BOOP) in lung transplant recipients. *Chest.* 1996;1100:1150-1154.
  63. Siddiqui MT, Garrity ER, Husain AN. Bronchiolitis obliterans organizing pneumonia—like reactions. *Hum Pathol.* 1996;27:714-719.
  64. Verberckmoes R, Verbeken E, Verschakelen J, Vanrenterghem Y. BOOP after renal transplantation. *Nephrol Dial Transplant.* 1996;11:1862-1863.
  65. Van Laar JM, Holscher HC, van Krieken JHJM, Stolk J. Bronchiolitis obliterans organizing pneumonia after adjuvant radiotherapy for breast carcinoma. *Respir Med.* 1997;91:241-244.
  66. Crestani B, Valeyre D, Roden S, Wallaert B, Dalphin JC, Cordier JF. Bronchiolitis obliterans organizing pneumonia syndrome primed by radiation therapy to the breast. *Am J Respir Crit Care Med.* 1998;158:1929-1935.
  67. Arbetter KR, Prakash UBS, Tazelaar HD, Douglas WW. Radiation-induced pneumonitis in the "non-irradiated" lung. *Mayo Clin Proc.* 1999;74:27-36.
  68. Majori M, Poletti V, Curti A, Corradi M, Falcone F, Pesci A. Bronchoalveolar lavage in bronchiolitis obliterans organizing pneumonia primed by radiation therapy to the breast. *J Allergy Clin Immunol.* 2000;105:239-244.
  69. Camus P, Nemery B. A novel cause for bronchiolitis obliterans organizing pneumonia: exposure to paint aerosols in textile workshops. *Eur Respir J.* 1998;11:259-262.
  70. Kadi FO, Abdesslam T, Nemery B. Five-year follow-up of Algerian victims of the "Ardystil syndrome." *Eur Respir J.* 1999;13:940-941.
  71. Bates C, Read RC, Morice AH. A malicious mould. *Lancet.* 1997;349:1598.
  72. Srivastava S, Haddad R, Kleinman G, Manthous CA. Erythema nodosum after smoke inhalation-induced bronchiolitis obliterans organizing pneumonia. *Crit Care Med.* 1999;27:1214-1216.
  73. Tenholder MF, Becker GL, Cervoni MI. The myelodysplastic syndrome in a patient with relapsing bronchiolitis obliterans organizing pneumonia. *Chest.* 1992;102:1895-1897.
  74. Mana F, Mets T, Vincken W, Sennesael J, Vanwaeyenbergh J, Goossens A. The association of bronchiolitis obliterans organizing pneumonia, systemic lupus erythematosus and Hunner's cystitis. *Chest.* 1993;104:642-644.
  75. Yamamoto M, Ina Y, Kitaichi M, Harasawa M, Tamura M. Clinical feature of BOOP in Japan. *Chest.* 1992;102(suppl):21S-25S.
  76. Spiteri MA, Klenerman P, Shepard MN, Padley S, Clark TJK, Newman-Taylor A. Seasonal cryptogenic organizing pneumonia with biochemical cholestasis: a new clinical entity. *Lancet.* 1992;340:281-284.
  77. Sanito NJ, Morley TF, Condoluci DV. Bronchiolitis obliterans organizing pneumonia in an AIDS patient. *Eur Respir J.* 1995;8:1021-1024.
  78. Ghidini A, Mariani E, Patreggiani C, Marinetti E. Bronchiolitis obliterans organizing pneumonia in pregnancy. *Obstet Gynecol.* 1999;94:843.
  79. Camus P, Piard F, Ashcroft T, et al. The lung in inflammatory bowel disease. *Medicine.* 1993;72:151-183.
  80. Safadi R, Berkman N, Haviv YS, Ben-Yehuda A, Amir G, Naparstek Y. Primary non-Hodgkin's lymphoma of the lung presenting as bronchiolitis obliterans organizing pneumonia. *Leuk Lymphoma.* 1997;28:209-213.
  81. Vaiman E, Odeh M, Attias D, Ben-Arie Y, Oliven A. T-cell chronic lymphocytic leukemia with pulmonary involvement and relapsing BOOP. *Eur Respir J.* 1999;14:471-474.
  82. Matsuo K, Tada S, Kataoka M, et al. Bronchiolitis obliterans organizing pneumonia (BOOP) in a case of smoldering adult T-cell leukemia. *Respirology.* 2000;5:81-85.
  83. Strobel ES, Bonnet RB, Werner P, Schafer HE, Peter HH. Bronchiolitis obliterans organizing pneumonia and primary biliary cirrhosis—like lung involvement in a patient with primary biliary cirrhosis. *Clin Rheumatol.* 1998;17:246-249.
  84. Guzman EJ, Smith AJ, Tietjen PA. Bronchiolitis obliterans organizing pneumonia after coronary artery bypass graft surgery. *J Thorac Cardiovasc Surg.* 2000;119:382-383.