

Barrett's Esophagus

Update on Screening, Surveillance, and Treatment

Thomas G. Morales, MD; Richard E. Sampliner, MD

The last 2 decades have seen dramatic advances in Barrett's esophagus. The definition has evolved; the rising incidence of adenocarcinoma has been recognized; and effective therapy to control gastroesophageal reflux disease has been developed. Both proton pump inhibitor therapy and laparoscopic fundoplication represent major developments. Studies of patients with dysplasia have helped to clarify appropriate surveillance intervals and treatment strategies for these patients, although controversy still exists. The possibility of reversing Barrett's esophagus in selected high-risk patients offers major hope for the future prevention of adenocarcinoma of the esophagus.

Arch Intern Med. 1999;159:1411-1416

Barrett's esophagus, which is a consequence of chronic gastroesophageal reflux disease (GERD), represents a metaplastic change from the normal squamous-lined esophagus to intestinal metaplasia, also referred to as *specialized columnar epithelium*.¹ The pathogenesis of this entity was actually not recognized by the British surgeon Norman Barrett, after whom the condition has been named. It has since been shown that reflux of gastric contents leads to Barrett's esophagus due to chronic inflammatory injury from acid and pepsin. More recent evidence suggests that bile acids can play a role in the setting of duodenogastroesophageal reflux and can contribute to esophageal mucosal injury as well.²

As an eroded or ulcerated area in the distal esophagus heals, it may be reepithelialized by multipotential stem cells, which may differentiate into specialized columnar epithelium characterized by goblet cells. The importance of the metaplastic process associated with Barrett's esophagus lies in the fact that the vast majority of esophageal adenocarcinomas arise from intestinal metaplasia, and the incidence of this cancer has been found to be rapidly rising in recent years.³

SCOPE OF THE PROBLEM

In patients with long-standing symptoms of reflux disease, the prevalence of Barrett's esophagus is at least 10%, and may be up to three times higher in those who are found to have erosive esophagitis.⁴ A study by Cameron et al⁵ suggested that the prevalence of Barrett's esophagus at autopsy was about 20 times higher in the general population than in those who seek medical care for reflux symptoms.

Based on prospective studies, the incidence of adenocarcinoma developing from Barrett's esophagus is approximately 1 per 100 patient-years.⁶ This represents a 30- to 125-fold increase risk over the general population. Thus, Barrett's esophagus is a relatively common lesion that has significant malignant potential.

WHEN IS ENDOSCOPY NECESSARY?

It is important to realize that Barrett's esophagus itself does not cause symptoms. The symptoms related to this entity are those of GERD, ie, heartburn or regurgitation. It is not possible to discriminate which patients with GERD symptoms have Barrett's esophagus based on the severity of symptoms.

In a recent community-based endoscopy series, the odds ratio for finding Barrett's esophagus in patients with GERD

From the Arizona Health Sciences Center, Tucson Veterans Affairs Medical Center, Tucson, Ariz. Dr Morales is now with Rocky Mountain Gastroenterology Associates, Wheat Ridge, Colo.

whose symptoms last longer than 5 years was 5.1 compared with those whose symptoms lasted for less than 1 year.⁷ Thus, it is believed that the chronicity of symptoms is more important than their severity in predicting Barrett's esophagus. For this reason, it is recommended that patients with chronic GERD symptoms of more than 5 years be referred for screening endoscopy to exclude Barrett's esophagus. Previous studies have defined a higher risk of Barrett's esophagus and esophageal adenocarcinoma in patients with GERD who are white, elderly, and male.^{8,9}

Other reasons for endoscopy in the setting of chronic GERD symptoms include dysphagia, unexplained weight loss, or anemia. Such "alarm" symptoms raise the suspicion of the occurrence of esopha-

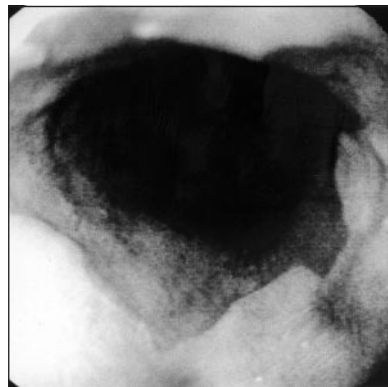


Figure 1. Endoscopic photograph of columnar-appearing mucosa suggestive of Barrett's esophagus. Histologic examination of biopsy specimens is necessary to confirm the diagnosis.

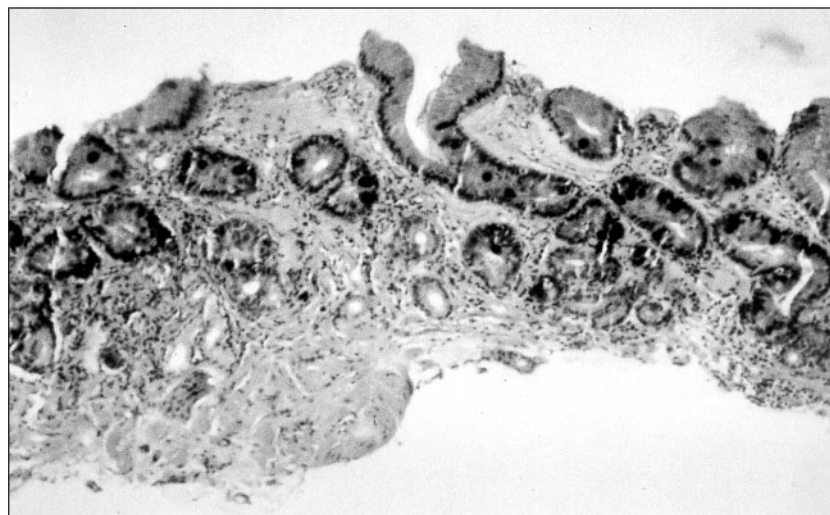


Figure 2. Histologic appearance of Barrett's esophagus with combined hematoxylin-eosin-alcian blue stain at a pH of 2.5. Goblet cells indicative of intestinal metaplasia are stained dark blue.

geal adenocarcinoma. Also, patients with GERD symptoms should be referred for diagnostic endoscopy if they do not respond as expected to acid suppressive therapy with proton pump inhibitor medications, regardless of whether alarm symptoms are present or the duration of symptoms has reached 5 years.

FROM ENDOSCOPY TO MICROSCOPY

Barrett's esophagus is a histologic diagnosis. At the time of endoscopy, intestinal metaplasia may be suspected on the basis of finding a segment of deep-red mucosa suggestive of columnar epithelium (**Figure 1**); however, the diagnosis is not confirmed until histologic examination reveals intestinal metaplasia.¹⁰ This particular epithelium has been associated with the highest risk of adenocarcinoma and is distinct from other types of columnar epithelium, including junctional-type epithelium, which resembles normal cardia mucosa, and gastric fundic-type epithelium, which resembles normal fundic mucosa.

All 3 types may have a similar endoscopic appearance, emphasizing the importance of biopsy confirmation. Most experts agree that endoscopic surveillance is warranted only for intestinal metaplasia that contains goblet cells (**Figure 2**). Combined staining with hematoxylin-eosin-alcian blue at a

pH of 2.5 is often helpful in identifying goblet cells and confirming intestinal metaplasia.

SHORT-SEGMENT BARRETT'S ESOPHAGUS AND INTESTINAL METAPLASIA OF THE GASTRIC CARDIA

It has been recognized that Barrett's esophagus may exist as short segments (<3 cm) in the distal esophagus and that such segments may be associated with esophageal adenocarcinoma.^{11,12} Therefore, there is no requirement for a specific length of intestinal metaplasia to make the diagnosis of Barrett's esophagus. It is not yet clear whether short segments of Barrett's esophagus, which may be identified in up to 15% of patients presenting for upper endoscopy, carry an equivalent risk of adenocarcinoma when compared with longer segments.^{13,14}

Further studies have found that intestinal metaplasia may also be detected frequently in the gastric cardia.¹⁵ However, preliminary studies suggest that this entity is associated with *Helicobacter pylori* infection, and not with GERD symptoms, esophagitis, or Barrett's esophagus.¹⁵⁻¹⁷ It is not yet clear whether intestinal metaplasia of the gastric cardia is a precursor lesion for adenocarcinoma of the cardia, or whether surveillance endoscopy is beneficial for patients with this disorder. However, its occurrence emphasizes the need for careful endoscopic delineation of the distal esophagus and differentiation between intestinal metaplasia of the esophagus and proximal stomach.

MARKERS FOR INCREASED CANCER RISK

The prognosis for esophageal cancer identified after symptoms develop remains poor, with an average survival of less than 1 year and an overall 5-year survival rate of less than 10%. Therefore, emphasis has been placed on the early detection of neoplasia within Barrett's esophagus. Recent studies have focused on the potential usefulness of DNA ploidy abnormalities and mutations of p53 as markers for increased cancer risk in Barrett's

esophagus.^{18,19} While these markers may eventually make their way into clinical practice, at this time they are considered research tools. Thus far, the most promising marker of increased cancer risk is the presence of dysplasia.

The finding of dysplasia in Barrett's esophagus offers the potential to intervene at a point prior to the development of invasive adenocarcinoma, with an opportunity to improve the patient's survival. Dysplasia has been defined as neoplastic epithelium confined to the basement membrane from which it arose. It has been subdivided into low-grade, or indefinite, dysplasia and high-grade dysplasia. In low-grade dysplasia, the nuclei are enlarged, crowded, and hyperchromatic, and may be stratified, but are confined to the lower half of the cells. In high-grade dysplasia, there is distortion of the crypt architecture with cribriform or "back-to-back" glands. The abnormalities seen in low-grade dysplasia are more pronounced in high-grade dysplasia, and the nuclear abnormalities reach the luminal surface of the cells. Epithelium that is not unequivocally positive or negative for dysplasia is termed *indefinite* and is usually considered in the same category as low-grade dysplasia.

The evidence that dysplasia precedes cancer is based on the frequent finding of high-grade dysplasia in the mucosa surrounding esophageal adenocarcinoma and the progression of high-grade dysplasia to adenocarcinoma in prospective series. Thus, it has been hypothesized that adenocarcinoma in Barrett's esophagus arises through a sequence of events beginning with chronic GERD and leading to intestinal metaplasia, dysplasia, and, ultimately, cancer.

NEW TECHNIQUES FOR IDENTIFYING DYSPLASIA

The standard technique for detecting dysplasia within Barrett's esophagus is endoscopic biopsy. This procedure requires that the patient return for periodic surveillance endoscopies, with multiple biopsy specimens obtained from the segment of Barrett's esophagus. Of key importance in this process is the fact

that most cases of dysplasia occur in the absence of an endoscopically visible lesion.²⁰ Recently, methylene blue staining has been used to help improve the detection of intestinal metaplasia and dysplasia.²¹ Methylene blue reversibly stains actively absorbing cells such as those found in intestinal-type mucosa. Biopsy specimens harboring dysplasia have been found to be much more likely to exhibit positive staining with methylene blue than biopsy specimens without dysplasia; therefore, this staining technique may enhance the yield of diagnostic endoscopic biopsy specimens.

Two other recent studies have looked at alternative techniques for identifying dysplasia. In one study, balloon cytology was used to detect dysplasia.²² This technique is attractive, since it does not require endoscopy and thus may lead to decreased costs and improved patient convenience. Abnormal cells suggestive of neoplasia were cytologically identified in 8 of 10 patients who had either adenocarcinoma or high-grade dysplasia by histologic diagnosis from endoscopic biopsy specimens. However, the cellularity obtained with the current balloon device was low, such that intestinal metaplasia diagnostic of Barrett's esophagus was found in only 24% of patients. Further studies are needed before this technique makes its way into routine clinical practice.

Another recent study used laser-induced fluorescence spectroscopy during upper endoscopy to identify high-grade dysplasia.²³ This technique uses "optical" as opposed to "pinch" biopsy specimens, which makes it less invasive and provides objective results at the time of endoscopy. When compared with the histologic results by endoscopic biopsy, spectroscopy correctly identified 70% of patients without dysplasia as having nonneoplastic mucosa, while the rest were diagnosed as premalignant. All patients with high-grade dysplasia were correctly identified by the technique in the small sample of patients studied. Thus, although the apparent low specificity of this technique with regard to nondysplastic mucosa requires further evaluation, laser-

induced spectroscopy has significant potential as a rapid, real-time technique for identifying high-grade dysplasia in Barrett's esophagus.

ENDOSCOPIC SURVEILLANCE FOR BARRETT'S ESOPHAGUS

Standard management for surgically fit patients with Barrett's esophagus is entry into an endoscopic surveillance program. Although the cost effectiveness of this process has not been validated in prospective studies, there is indirect evidence to support its use. A recent study evaluated a group of 166 patients with Barrett's esophagus who underwent yearly surveillance endoscopy for a mean of almost 3 years.²⁴ Adenocarcinoma developed in 6 patients and high-grade dysplasia developed in 4. Of the patients with cancer, only one had node-positive disease at resection. This group was compared with a group of 25 consecutive surgically resected patients with esophageal adenocarcinoma who had not undergone surveillance. Of this group, 52% had node-positive disease. Thus, endoscopic surveillance appeared to detect cancers at an earlier stage when they did occur. The cost-effectiveness of endoscopic surveillance in this study was found to compare favorably with other preventive programs, such as fecal occult blood testing for colon cancer and mammography for breast cancer.

The optimal frequency of endoscopic surveillance has yet to be defined. A recent decision analysis study using a computer cohort simulation found that endoscopy every 2 to 3 years provides the greatest quality-adjusted life expectancy, but when costs are the main consideration, examinations every 5 years still improve life expectancy, while yielding cost-effectiveness ratios similar to those of other preventive medical practices.²⁵

The frequency of surveillance examinations should be altered depending on the degree of dysplasia identified. What is an appropriate interval in patients without any dysplasia? To help answer this question, one must examine the risk that such patients have for going on to develop dysplasia or adenocarcinoma. Interestingly, the data on such

patients are limited to prospective series from only 5 different centers (**Table**).²⁶⁻³² These studies reveal that each year 4% to 11% per year of patients with Barrett's esophagus went on to develop dysplasia. With regard to risk of adenocarcinoma, only 5 (3%) of 150 patients developed cancer over follow-up periods ranging from 3.6 to 10 years. These data favor a surveillance interval of at least 3 years for individuals with Barrett's esophagus who have never had dysplasia detected (**Figure 3**).

Prospective data on the development of esophageal adenocarcinoma from low-grade dysplasia are also limited. Only 45 patients with low-grade dysplasia have been prospectively evaluated over an interval of 1.4 to 4.3 years. Eight (18%) have developed cancer over this time frame. Given the association with cancer and potential sampling error, endoscopy should be repeated after the first detection of low-grade dysplasia in an attempt to confidently exclude concomitant cancer. Subsequent endoscopy with

biopsy is recommended at 6-month intervals over the next year and again after another 12 months if no dysplasia is detected. Low-grade dysplasia may regress, and this may be a reflection of cellular atypia owing to prior inflammatory changes, sampling error, or true resolution. Therefore, if no further dysplasia is noted over a 2-year period it would be reasonable to increase the surveillance interval to 2 to 3 years. If, after 2 years, low-grade dysplasia is still present but has not progressed, then yearly surveillance is advised.

The treatment of individuals with high-grade dysplasia is controversial. Some experts believe that such patients should undergo esophagectomy, given the high risk of cancer, while others believe that close endoscopic surveillance is sufficient. One study reported that an aggressive biopsy protocol could accurately distinguish patients with high-grade dysplasia from those with early adenocarcinoma.²⁹ However, the biopsy protocol described was quite intensive and not practical for the routine clinical setting. A recent study found that even such a rigorous biopsy protocol used in a research setting could not completely exclude concurrent cancer, as 4 of 12 patients (mean age, 58 years) with high-grade dysplasia were found to have cancer at esophagectomy.³³

Even if one could confidently exclude invasive cancer when high-grade dysplasia is identified, the risk of subsequent progression to cancer is high. Prospective series reveal that 32 (28%) of 115 patients with high-grade dysplasia went on to develop adenocarcinoma over a period of up

to 9.5 years. These data, which support esophagectomy for such patients, have been tempered by recent evidence that a significant proportion of these patients may have regression of the high-grade dysplasia over time. In one study, 27% of patients had lesser grades of dysplasia or no dysplasia on subsequent follow-up.³⁰ Also, even expert centers continue to report operative mortality rates as high as 3% to 6% and morbidity rates as high as 40% for esophagectomy.^{34,35} Therefore, some experts advise continued surveillance for individuals with high-grade dysplasia and reserve esophagectomy only for those who develop adenocarcinoma. They argue that, with close surveillance at 3- to 6-month intervals, if cancer is detected, esophagectomy will be curative in most patients. Further, the morbidity and mortality of esophagectomy will be avoided in those whose high-grade dysplasia might regress or remain unchanged.

However, clinical data from surgical series indicate that when esophagectomy is undertaken for high-grade dysplasia there is a good chance that unsuspected adenocarcinoma will be identified. Collective series of patients undergoing esophagectomy for high-grade dysplasia reveal that 50 (41%) of 122 patients had concomitant cancer in the resected specimen.³⁶ Also, recent surgical studies have found that patients with Barrett's esophagus who have esophageal adenocarcinoma detected at the time of surgical resection for high-grade dysplasia are likely to have resectable disease and have an improved 5-year survival as compared with those whose cancer was detected outside a surveillance program.^{37,38} These data show that if esophagectomy is performed for high-grade dysplasia, cancer will often be removed at a curative stage. Thus, after confirmation of high-grade dysplasia by an expert pathologist, surgical resection by an experienced esophageal surgeon should be considered if the patient is medically fit.

Prospective Development of Esophageal Adenocarcinoma Based on Grade of Dysplasia*

Grade of Dysplasia	No. of Patients	No. (%) of Patients With Cancer	Length of Follow-up, y
None	150	5 (3)	3.6-10
Low grade	45	8 (18)	1.5-4.3
High grade	115	32 (28)	0.2-9.5

*From references 25 through 31; groups are not mutually exclusive.

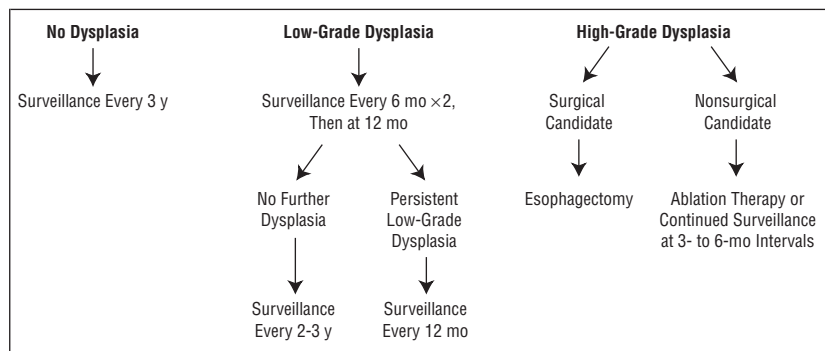


Figure 3. Proposed surveillance and management algorithm for patients with Barrett's esophagus based on the grade of dysplasia detected by endoscopy with biopsies. Low-grade dysplasia arm assumes that a follow-up endoscopy with biopsy has been performed to exclude concomitant cancer. High-grade dysplasia arm assumes confirmation of diagnosis by expert pathologist.

THERAPY FOR BARRETT'S ESOPHAGUS

The aim of therapy for Barrett's esophagus is to control the symptoms of GERD. This control is usu-

ally best accomplished with proton pump inhibitor therapy. Higher-than-standard dosing may be necessary to control symptoms in patients with Barrett's esophagus. Even high-dose therapy may not prevent nocturnal regurgitation.³⁹

Patients can be found who have Barrett's esophagus, but apparently lack GERD symptoms. They may have undergone endoscopy to evaluate non-GERD symptoms, such as abdominal pain or gastrointestinal bleeding. Such patients should still undergo a trial of proton pump inhibitor therapy, as they may have accommodated to chronic GERD symptoms. These patients often feel better in retrospect after a course of therapy.

Patients whose symptoms are inadequately relieved with pharmacologic therapy, who have prominent extraesophageal manifestations of GERD, or who prefer an alternative to long-term medication use are candidates for antireflux surgery. Laparoscopic fundoplication has impressive short-term benefit in relation to control of symptoms and esophageal acid exposure.⁴⁰ Long-term data regarding the durability of this procedure are awaited.

NEW TECHNIQUES FOR THE TREATMENT OF BARRETT'S ESOPHAGUS

An exciting experimental approach to Barrett's esophagus is endoscopic ablation therapy combined with proton pump inhibition. Ablation therapy includes such techniques as photodynamic therapy, multipolar polar electrocautery, laser therapy, and, most recently, argon plasma coagulation. These treatments have the potential to reverse Barrett's esophagus to normal squamous mucosa by injuring the intestinal metaplastic epithelium and allowing it to heal in a reduced-acid environment. Early evidence suggests that these techniques may even be effective once dysplasia has developed.

Photodynamic therapy involves the use of photosensitizing agents that selectively concentrate within neoplastic tissue, which is then destroyed by the application of

light via a tunable dye laser. Depending on the type and dose of photosensitizing agent used, early studies report some success in eliminating Barrett's esophagus, including that containing dysplasia and cancer.⁴¹ Frequent complications of this technique include patient sensitivity to light and esophageal strictures.

Multipolar polar electrocautery uses an electrocautery probe that transmits electrical energy to the epithelium to cause a superficial injury. This therapy is more convenient to apply and is more readily available in most endoscopy units than photodynamic therapy. Along with laser therapy, this technique has been used in patients with Barrett's esophagus and has been shown to lead to reversal of intestinal metaplasia.⁴²⁻⁴⁴ To our knowledge, there are currently no published series examining the role of these 2 therapies in patients with dysplasia. Early animal studies reveal that argon plasma coagulation, another non-contact electrocautery method, may also become a viable option for ablation of Barrett's epithelium.⁴⁵ It is important to note that in some cases ablation therapy has led to reepithelialization over intestinal metaplasia. The potential exists that this epithelium may still harbor a neoplastic risk.

In summary, ablation therapy of Barrett's esophagus with dysplasia remains experimental. Studies specifically targeted to patients with low-grade dysplasia are needed. In the future, we may be able to use other markers, such as p53 accumulation, that will enhance our ability to select for therapy those patients with the highest risk of developing cancer. Although of unproved long-term value given the variable natural history of high-grade dysplasia, ablation therapy is currently a reasonable experimental approach for patients who have major comorbidity that precludes surgery or who are averse to surgical therapy.

CONCLUSIONS

An accepted risk factor for Barrett's esophagus is a long duration (at least 5 years) of reflux symptoms. With this presentation, especially in older white men, screening endoscopy

to identify the lesion is recommended. Given the increased risk of esophageal adenocarcinoma in patients with Barrett's esophagus, periodic surveillance endoscopy with biopsy should be performed. However, screening and surveillance endoscopy should only be performed in medically fit patients who will agree to consider surgical therapy should high-grade dysplasia or a resectable cancer be identified. New methods of detecting dysplasia and more specific markers for neoplasia should improve the tolerability and reliability of the surveillance process. Finally, ablative techniques may ultimately lead to the ability to reverse Barrett's esophagus in selected patients.

Accepted for publication October 8, 1998.

Corresponding author: Thomas G. Morales, MD, Rocky Mountain Gastroenterology Associates, 8550 W 38th Ave, Suite 300, Wheat Ridge, CO 80033.

REFERENCES

1. Hamilton SR. Pathogenesis of columnar lined (Barrett's) esophagus. In: Spechler SJ, Goyal RK, eds. *Barrett's Esophagus: Pathophysiology, Diagnosis, and Management*. New York, NY: Elsevier Science Inc; 1985:29-37.
2. Vaezi MF, Richter JE. Role of acid and duodenogastroesophageal reflux in gastroesophageal reflux disease. *Gastroenterology*. 1996;111:1192-1199.
3. Blot WJ, Devesa SS, Kneller RW, Fraumeni JF. Rising incidence of adenocarcinoma of the esophagus and gastric cardia. *JAMA*. 1991;265:1287-1289.
4. Winters C, Spurling TJ, Chobanian SJ, et al. Barrett's esophagus: a prevalent occult complication of gastroesophageal reflux disease. *Gastroenterology*. 1987;92:118-124.
5. Cameron AJ, Zinsmeister AR, Ballard DJ, Carney JA. Prevalence of columnar-lined (Barrett's) esophagus: comparison of population-based and autopsy findings. *Gastroenterology*. 1990;99:918-922.
6. Drewitz DJ, Sampliner RE, Garewal HS. The incidence of adenocarcinoma in Barrett's esophagus: a prospective study of 170 patients followed 4.8 years. *Am J Gastroenterol*. 1997;92:212-215.
7. Lieberman DA, Oehlke M, Helfand M, and the GORGE Conortium. *Am J Gastroenterol*. 1997; 92:1293-1297.
8. Smith RRL, Hamilton SR, Boitnott JK, Rogers EL. The spectrum of carcinoma arising in Barrett's esophagus: a clinicopathologic study of 26 patients. *Am J Surg Pathol*. 1984;8:563-573.
9. Spechler SJ, Robbins AH, Rubins HB, et al. Adenocarcinoma and Barrett's esophagus: an overrated risk? *Gastroenterology*. 1984;87:927-933.

10. Paull A, Trier JS, Dalton MD, Camp R, Loeb P, Goyal RK. The histologic spectrum of Barrett's esophagus. *N Engl J Med*. 1976;295:476-480.
11. Hamilton SR, Smith RRL, Cameron JL. Prevalence and characteristics of Barrett's esophagus in patients with adenocarcinoma of the esophagus or esophagogastric junction. *Hum Pathol*. 1988;19:942-948.
12. Schnell TG, Sontag SJ, Chejfec G. Adenocarcinomas arising in tongues or short segments of Barrett's esophagus. *Dig Dis Sci*. 1992;37:137-143.
13. Weston AP, Krmpotich P, Cherman R, et al. Prospective long-term endoscopic and histological follow-up of short segment Barrett's esophagus: comparison with traditional long segment Barrett's esophagus. *Am J Gastroenterol*. 1997;92:407-413.
14. Sharma P, Morales TG, Bhattacharyya A, Garewal HS, Sampliner RE. Dysplasia in short-segment Barrett's esophagus: a prospective 3-year follow-up. *Am J Gastroenterol*. 1997;92:2012-2016.
15. Morales TG, Sampliner RE, Bhattacharyya A. Intestinal metaplasia of the gastric cardia. *Am J Gastroenterol*. 1997;92:414-418.
16. Goldblum JR, Vicari JJ, Falk GW, et al. Inflammation and intestinal metaplasia of the gastric cardia: the role of gastroesophageal reflux and *H. pylori* infection. *Gastroenterology*. 1998;114:633-639.
17. Morales TG, Bhattacharyya A, Johnson C, Sampliner RE. Is Barrett's esophagus associated with intestinal metaplasia of the gastric cardia? *Am J Gastroenterol*. 1997;92:1818-1822.
18. Galipeau PC, Cowan DS, Sanchez CA, et al. 17p (p53) allelic losses, 4N (G2/tetraploid) populations, and progression to aneuploidy in Barrett's esophagus. *Proc Natl Acad Sci U S A*. 1996;93:7081-7084.
19. Younes M, Ertan A, Lechago L, Somoano J, Lechago J. P53 protein accumulation is a specific marker of malignant potential in Barrett's metaplasia. *Dig Dis Sci*. 1997;42:697-701.
20. Haggitt RC. Barrett's esophagus, dysplasia and adenocarcinoma. *Hum Pathol*. 1994;25:982-993.
21. Canto MIF, Setrakian S, Petras RE, Blades E, Chak A, Sivak MV. Methylene blue selectively stains intestinal metaplasia in Barrett's esophagus. *Gastrointest Endosc*. 1996;44:1-7.
22. Falk GW, Chtajallu R, Goldblum JR, et al. Surveillance of patients with Barrett's esophagus for dysplasia and cancer with balloon cytology. *Gastroenterology*. 1997;112:1787-1797.
23. Panjehpour M, Overholt BF, Vo-Dihn T, Haggitt RC, Edwards DH, Buckley FP. Endoscopic fluorescence detection of high-grade dysplasia in Barrett's esophagus. *Gastroenterology*. 1996;111:93-101.
24. Wright TA, Gray MR, Morris AI, et al. Cost effectiveness of detecting Barrett's esophagus. *Gut*. 1996;39:574-579.
25. Provenzale D, Kemp JA, Arora S, Wong JB. A guide for surveillance of patients with Barrett's esophagus. *Am J Gastroenterol*. 1994;89:670-680.
26. Robertson CS, Mayberry JF, Nicholson DA, James PD, Atkinson M. Value of endoscopic surveillance in the detection of neoplastic change in Barrett's oesophagus. *Br J Surg*. 1988;75:760-763.
27. Hameeteman W, Tytgat GN, Houthoff HJ, van den Tweel JG. Barrett's esophagus: development of dysplasia and adenocarcinoma. *Gastroenterology*. 1989;96:1249-1256.
28. Miros M, Kerlin P, Walker N. Only patients with dysplasia progress to adenocarcinoma in Barrett's oesophagus. *Gut*. 1991;32:1441-1446.
29. Reid BJ, Blount PL, Rubin CE, Levine DS, Haggitt RC, Robinovitch PS. Flow-cytometric and histological progression to malignancy in Barrett's esophagus: prospective endoscopic surveillance of a cohort. *Gastroenterology*. 1992;102:1212-1219.
30. Levine DS, Haggitt RC, Blount PL, Robinovitch PS, Rusch VW, Reid BJ. An endoscopic biopsy protocol can differentiate high-grade dysplasia from early adenocarcinoma in Barrett's esophagus. *Gastroenterology*. 1993;105:40-50.
31. Levine DS, Haggitt RC, Irvine S, Reid BJ. Natural history of high-grade dysplasia in Barrett's esophagus [abstract]. *Gastroenterology*. 1996;110:A550.
32. Schnell T, Sontag SJ, Chejfec G, et al. High grade dysplasia (HGD) is not an indication for surgery in patients (Pts) with Barrett's esophagus (BE) [abstract]. *Gastroenterology*. 1996;110:A590.
33. Falk GW, Rice TW, Goldblum JR, Richter JE. Seattle biopsy protocol with jumbo biopsy forceps still misses unsuspected cancers in Barrett's esophagus with high-grade dysplasia [abstract]. *Gastrointest Endosc*. 1997;45:AB68.
34. Rice TW, Falk GW, Achkar E, Petras RE. Surgical management of high-grade dysplasia in Barrett's esophagus. *Am J Gastroenterol*. 1993;88:1832-1836.
35. Heitmiller RF, Redmond M, Hamilton SR. Barrett's esophagus with high-grade dysplasia: an indication for prophylactic esophagectomy. *Ann Surg*. 1996;224:66-71.
36. Edwards MJ, Gable DR, Lentsch, Richardson JD. The rationale for esophagectomy as the optimal therapy for Barrett's esophagus with high-grade dysplasia. *Ann Surg*. 1996;223:585-591.
37. Peters JH, Clark GW, Ireland AP, Chandrasoma P, Smyrk TC, DeMeester TR. Outcome of adenocarcinoma arising in Barrett's esophagus in endoscopically surveyed and nonsurveyed patients. *J Thorac Cardiovasc Surg*. 1994;108:813-822.
38. Streitz JM, Andrews CW, Ellis FH. Endoscopic surveillance of Barrett's esophagus: does it help? *J Thorac Cardiovasc Surg*. 1993;105:383-388.
39. Sampliner R. Effect of up to three years of high-dose lansoprazole on Barrett's esophagus. *Am J Gastroenterol*. 1994;89:1844-1848.
40. Hunter J, Trus TL, Branum GD, Waring JP, Wood WC. A physiologic approach to laparoscopic fundoplication for gastroesophageal reflux disease. *Ann Surg*. 1996;223:673-678.
41. Overholt BF, Panjehpour M. Photodynamic therapy for Barrett's esophagus: clinical update. *Am J Gastroenterol*. 1996;91:1719-1723.
42. Sampliner RE, Fennerty MB, Garewal HS. Reversal of Barrett's esophagus with acid suppression and multipolar electrocoagulation: preliminary results. *Gastrointest Endosc*. 1996;44:532-535.
43. Sampliner RE, Hixson LJ, Fennerty MB, Garewal HS. Regression of Barrett's esophagus by laser ablation in an anacid environment. *Dig Dis Sci*. 1993;38:365-368.
44. Berenson MM, Johnson TD, Markowitz NR, Buchi KN, Samowitz WS. Restoration of squamous mucosa after ablation of Barrett's esophageal epithelium. *Gastroenterology*. 1993;104:1686-1691.
45. Heier SK, Heier LM, Josephs M, et al. Argon plasma coagulation: comparison to other candidate therapies for Barrett's ablation using the canine esophagus [abstract]. *Gastrointest Endosc*. 1997;45:AB31.