

Antimicrobial Photosensitive Reactions

Snejina G. Vassileva, MD; Grisha Mateev, MD; Lawrence Charles Parish, MD

Photosensitivity reactions are recognized as unwanted adverse effects of an array of commonly administered topical or systemic medications, including nonsteroidal anti-inflammatory agents, antifungals, and antimicrobials. When a drug induces photosensitivity, exogenous molecules in the skin absorb normally harmless doses of visible and UV light, leading to an acute inflammatory response. In phototoxic reactions, the damage to tissues is direct; in photoallergic reactions, it is immunologically mediated. In vitro and in vivo assay systems can assist in predicting or confirming drug photosensitivity. The incidence of photosensitivity reactions may be too low to be detected in clinical studies and may become recognized only in the postmarketing stage of drug development. Some drugs have been withdrawn because of photosensitivity effects that appeared after general release. Photosensitivity reactions have been studied for a number of topical antimicrobials and for the sulfonamides, griseofulvin, the tetracyclines, and the quinolones. Incidence and intensity of drug phototoxicity can vary widely among the different compounds of a given class of antimicrobials. When phototoxic effects are relatively low in incidence, mild, reversible, and clinically manageable, the benefits of an antimicrobial drug may well outweigh the potential for adverse photosensitivity effects. *Arch Intern Med.* 1998;158:1993-2000

Photosensitivity caused by drug reactions may be defined as unwanted pharmacological effects produced when the skin is sensitized by topical or systemic medications, or both, and exposed to UV rays, either artificially or naturally. Such peculiar and often distressing photobiologic reactions are commonly considered to be the undesirable adverse effects of commonly administered drugs such as phenothiazines, amiodarones (antiarrhythmics), nonsteroidal anti-inflammatory agents, and antimicrobials. Often the benefits of many of these pharmaceuticals far outweigh the problems they present in the presence of UV light.

Photosensitivity reactions have been recognized for hundreds of years. In the 13th century, the Arab scholar Ibn El-Bitar noted that certain plant extracts could be com-

bined with exposure to sunlight to treat vitiligo.¹ These herbal remedies were rediscovered in the 1940s and identified as containing the phototoxic furocoumarins (psoralens). The photobiologic activity of psoralens has been used in modern photochemotherapy to treat an increasing number of chronic inflammatory dermatoses. Many antiviral compounds obtained from plants, eg, thiophenes, polyacetylenes, furyl compounds, and alkaloids, are also photosensitizers, and their biological properties are dependent on or augmented by light of specific wavelengths, commonly long-wave UV-A.² While researchers continue to examine the potential of such compounds for antiviral therapy and have identified several substances that are phototoxic to human immunodeficiency virus (serotype 1),^{3,4} the adverse photosensitivity effects of current pharmaceuticals are of more immediate clinical relevance.

Photosensitivity has frequently been associated with local antiseptics,

From the Department of Dermatology, Medical University-Sofia, Sofia, Bulgaria (Drs Vassileva and Mateev); and the Jefferson Center for International Dermatology, Jefferson Medical College of Thomas Jefferson University, Philadelphia, Pa (Dr Parish).

antifungals (eg, griseofulvin), and the antimicrobials nalidixic acid, fluoroquinolones, sulfonamides, tetracyclines, and antiprotozoans. Although such reactions rarely involve the morbidity and mortality seen with other adverse effects, including toxic epidermal necrolysis, Stevens-Johnson syndrome, anaphylaxis, or systemic toxicity, they do constitute a common dermatologic and pharmaceutical concern.⁵ Not infrequently, the incidence of photosensitivity reactions to antimicrobials is too low to be detected even in very careful analyses of phase 2 and 3 clinical studies. During the postmarketing period, when larger groups of outpatients are exposed to direct sunlight, photosensitivity may be recognized as a major deterrent to use of the drug. This was the case with nalidixic acid, a nonfluorinated quinolone uroantiseptic; an increased incidence of severe bullous photosensitivity reactions was seen following its introduction in 1962.⁶

The members of the tetracycline group have been reported to induce photosensitivity in 25% to 90% of patients receiving demethylchlortetracycline, 20% receiving doxycycline, 7% receiving methacycline, and more rarely for those receiving minocycline.⁷⁻⁹ For the fluoroquinolones, a rapidly growing group of new generation potent antibacterial quinolone derivatives, the reported incidence of photosensitivity varies from 1% to 4% for ciprofloxacin¹⁰ to 10% and even 19% for fleroxacin.¹¹ No member of these widely used systemic anti-infective agents has been withdrawn for photosensitivity adverse reactions, except temafloxacin.¹²

The problem of establishing the therapeutic parameters of a photosensitizing antimicrobial preparation may lead the clinician to completely reject its use, on the one hand, or underestimate its potential drawbacks in a non-life-threatening situation, on the other. The indications for the clinical use of most anti-infective agents should therefore rely on familiarity with the pathogenetic mechanisms, clinical presenta-

tions, diagnosis, and means of preventing potential photosensitivity reactions.

BIOPHYSICAL AND BIOCHEMICAL BACKGROUND

Photosensitization is a process in which reactions to normally innocuous radiation are induced in a biological system by the introduction of a specific radiation-absorbing substance, referred to as a photosensitizer.¹³ The latter causes another component of the system, a substrate, to be changed by radiation.

Photosensitivity reactions are induced by a delimited range of the electromagnetic spectrum that includes visible light and UV radiation. Ultraviolet (200-400 nm) and visible (400-800 nm) lights, to which the skin is continually exposed, are produced by the sun and artificial sources, such as tanning beds and fluorescent lamps. The UV spectrum is divided into 3 parts with arbitrary limits, ie, UV-A (wavelength 320-400 nm), also called black light; UV-B or "sunburn" radiation (wavelength 290-320 nm)¹⁴; and UV-C (wavelength 200-290 nm).¹³⁻¹⁵ Of these wavelengths, only UV-A and UV-B are involved in photosensitivity reactions, since UV-C is blocked by the ozone layer of the atmosphere. Ultraviolet radiation penetrates the skin to varying degrees before being transmitted or absorbed by molecules acting as substrates or endogenous chromophores. The latter include epidermal keratins, melanin, nucleic acids, hemoglobin, porphyrins, lipoproteins, carotene, and aromatic amino acids, such as tyrosine, tryptophan, and histidine.¹³

Photon absorption leads to an energy transfer, promoting the electron status of the chromophore molecule to an excited singlet state.¹³ Such an excited molecule is short-lived and can undergo several transformations. It may return to its ground state with the emission of heat (and sometimes fluorescence) or cross to a triplet state, in which the molecule is very active chemically and often reacts with other chemicals. Transformation from triplet to ground state allows sufficient time for energy transfer and

initiation of biological changes, consisting in damage of several macromolecules, particularly nuclear DNA. A third change involves molecules absorbing a sufficient amount of energy for the formation of free radicals. These are highly reactive and can lead to substantial chemical activity with surrounding tissue damage.^{13,14,16} Skin reacts to such UV damage with an acute inflammatory response, commonly known as sunburn.

In cases of drug photosensitivity, similar acute inflammatory reactions occur in the skin in the presence of foreign molecules (exogenous chromophores), which absorb normally harmless doses of UV and visible radiation and create an electronically excited state. Absorbed photons from the electromagnetic spectrum are converted into chemical energy used in chemical reactions. These can transform the original chemical into a photoproduct, transfer the energy to a protein molecule, or shed the energy as either light or heat.^{13,16} Clinically, this process can result in erythema, edema, and sometimes blistering, as well as an increase in melanin formation.

For most chemical photosensitizers, the absorption and the action spectra are nearly equal, lying either in the visible or UV range, usually UV-A and UV-B.¹⁷ Visible light-induced photosensitivity occurs with porphyrins, several dyes, and the fluoroquinolones to sulfloxacin, sparfloxacin, enoxacin, and clinafloxacin. Psoralens, nonsteroidal anti-inflammatory agents, phenothiazines, griseofulvin, sulfonamides, tetracyclines, nalidixic acid, and most fluoroquinolones react primarily with UV-A. A limited number of chemicals, for instance fleroxacin, depend mainly on UV-B activation.¹⁸ In vitro photosensitivity requiring both UV-A and UV-B have been reported with the quinolones, oxolinic acid, pipemidic acid, rosoxacin,¹⁸ and the newly developed fluoroquinolone sparfloxacin.¹⁹

MECHANISMS OF PHOTSENSITIVITY

Although the precise pathogenesis of drug-induced photosensitivity is not completely understood for all of the photosensitizing com-

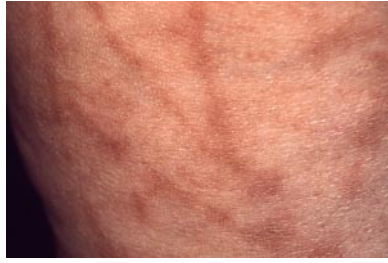

Figure 1. *Phytophotodermatitis caused by contact with parsley plant.*

pounds reported in the literature, several mechanisms play varying roles. Two principal types of reactions are generally accepted, regardless of the route of administration of the photosensitizer: phototoxicity and photoallergy. In a third category of reaction, photosensitizing drugs may induce or exacerbate disorders such as lupus erythematosus in which photosensitivity plays a prominent role.

Phototoxicity

Phototoxic reactions result from direct cellular damage produced by the photoproducts, provided enough of the chemical and radiation are present. No immunologic mechanisms are involved in phototoxic reactions, so they can manifest themselves during an initial exposure. Phytophotodermatitis caused by bergamot oil, parsley, celery, dates, and other plants containing the furocoumarins is a classic example of phototoxic reaction (**Figure 1**). At a molecular level, most phototoxic reactions (eg, in the case of acriflavine, porphyrins, chlorothiazide, tetracyclines, nonsteroidal anti-inflammatory agents, quinolones, and certain dyes, such as methylene blue) develop in the presence of oxygen, in which free radicals resulting from photo-oxidation and peroxidation processes cause injury to cell nuclei, cytoplasm, and cellular membrane components. Phototoxicity reactions to psoralens, although rarely requiring molecular oxygen, are for the most part oxygen independent. In those cases, UV-A-induced covalent binding (formation of cyclobutane dimers) between the chemical and the molecules of DNA occurs. Similar dimers are

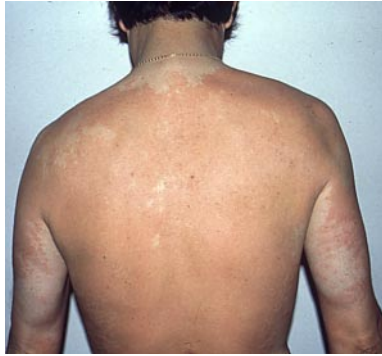

Figure 2. *Doxycycline-induced phototoxic eruption resembling sunburn.*

formed between chlorpromazine and RNA molecules.^{13,20} The factors that strongly influence the incidence, intensity, and clinical features of phototoxic reactions include (1) the nature, concentration, absorption, and pharmacokinetics of the drug; (2) quantity and spectrum of radiant energy; and (3) factors related to the skin thickness of the stratum corneum, quantity of melanin, temperature, and humidity.

Most phototoxic eruptions clinically resemble exaggerated sunburns and are characterized by rapid onset of a burning sensation, erythema, edema, and sometimes vesiculation (**Figure 2**). Eruptions develop shortly after exposure to light with intensity increasing in a dose-dependent manner. Persons with light skin (types I and II) seem to be more prone to develop phototoxic reactions, whereas in darker skins melanin offers some degree of protection.

A distinct type of phototoxic eruption consisting in diffuse pigmentation on light-exposed areas is reported in relation to several drugs, including amiodarone, chlorpromazine, minocycline, and quinine. The phototoxic effect of some drugs on nails is a well-known phenomenon referred to as photo-onycholysis. The latter may be the only manifestation of photosensitivity.

Pseudoporphyria, a condition clinically similar to porphyria cutanea tarda but lacking abnormalities in porphyrin metabolism, has been described as a variant of a phototoxic reaction in conjunction with sulfonamides, griseofulvin, nalidixic acid, and the tetracyclines.¹⁴

Photoallergy

Photoallergy refers to immunologically mediated photosensitivity reactions, in which immediate (humoral-mediated) hypersensitivity, delayed (cell-mediated) hypersensitivity, or both develop to a photoactivated compound (a drug or chemical) transformed into a hapten or a complete antigen during radiation.²⁰ In contrast to phototoxic reactions, photoallergy is usually elicited by the longer UV-A wavelengths (>315 nm). Photoallergic drug responses develop only in sensitized persons and are not dose dependent, although a sensitized person is likely to get a stronger reaction with a much higher dose.^{13,21,22} Cell-mediated responses require a latency period for the immunologic memory to develop after the first contact with the photosensitizer; on subsequent exposures the elicitation of response is shorter.^{21,22}

The delayed type of photoallergy is more frequent. The pathogenetic mechanisms of photoallergic reactions are quite similar to those seen in allergic dermatitis, ie, the photoantigen (hapten) is presented by epidermal Langerhans cells to T lymphocytes with all the subsequent features of delayed skin hypersensitivity response of lymphocytic infiltration, release of lymphokines, activation of mast cells, and increased cytokine expression.¹³

According to the mode of administration of the photosensitizer, photoallergic reactions can be classified as either contact photoallergic dermatitis or photoallergy induced by systemic agents.²¹ Several factors may influence the incidence, intensity, and some clinical features of photoallergic reactions: quantity and location of the drug on or in the skin; quantity, spectrum, and penetration capabilities of the activating radiation; thickness of the horny layer; degree of melanin pigmentation; and immunologic state of the affected person.¹⁶ The last seems to be of great importance, because photosensitivity reactions are found frequently in immunocompromised human immunodeficiency virus-infected patients.²³

Clinically, drug-induced photoallergic reactions can appear as solar urticaria or as eczematous or lichenoid dermatitis on predominantly light-exposed areas.^{13,14,20} The eruption usually disappears spontaneously once the offending photosensitizer has been removed. In rare instances, however, photosensitivity may persist longer and relapse with minimal UV radiation, despite the lack of contact with the photosensitizing substance. This condition, defined as persistent light reaction, is observed in relation to topical photosensitizers and, more rarely, through systemic photosensitization.^{13,20}

Diagnosis

Determining the exact mechanism of a photosensitivity reaction is important because phototoxins can be manipulated and rendered harmless by decreasing the dose or the amount of radiation, whereas photoallergic reactions do not significantly change with alterations in these parameters.²² Unfortunately, several agents confuse the issue by having both phototoxic and photoallergic mechanisms. These include the phenothiazines, quinolone derivatives, sulfonamides, and thiazide diuretics.^{21,22}

Drug-Induced Lupus Erythematosus

More than 70 drugs have been reported as causing symptoms and serologic markers of lupus erythematosus.²⁴ Drug-induced lupus resembles a mild form of systemic lupus erythematosus marked by the presence of antinuclear antibodies in the blood; this presence generally resolves on discontinuation of the drug.²⁵ Drugs associated with drug-induced lupus have no common chemical makeup or structure and seem to influence immune regulation in different ways,^{16,26} probably mimicking the spontaneous disease rather than unmasking an underlying diathesis.²⁷

Subacute cutaneous lupus erythematosus is the subtype of lupus erythematosus most frequently associated with photosensitivity. Symptoms of subacute cutaneous

Table 1. Drug-Induced Lupus Erythematosus (LE)*

Drugs Associated With Reactive LE Serology and/or Clinical Manifestation
Hydralazine
Procainamide
Isoniazid
Chlorpromazine
Methyldopa
Quinidine
Penicillamine
Cimetidine
β-Blockers
Oral contraceptives
Minocycline
Drugs Associated With LE and Photosensitivity
Griseofulvin
Hydrochlorothiazide
Sulfasalazine
Sulfonamides
Tetracycline
Psoralen-UV-A

*Data in this table from Harber and Baer,¹⁶ Cush and Goldings,²⁵ Gould et al.,²⁶ Alarcón-Segovia and Kraus,²⁷ Shapiro et al.,²⁸ Laversuch et al.,²⁹ and Miyagawa et al.³¹

lupus erythematosus include widespread symmetric superficial lesions, often of the shoulders, upper part of the chest, back, and neck, which evolve into psoriasiform or annular plaques. There is epidermal-dermal separation because of severe injury to the basal keratinocytes.²⁸ While numerous drugs can induce lupus erythematosus-type abnormalities, fewer have been reported as associated with subacute cutaneous lupus erythematosus and photosensitivity (**Table 1**). Those that have include hydrochlorothiazide, griseofulvin,²⁶ and, more rarely, sulphasalazine.²⁹

The mechanism of photosensitivity reactions in drug-induced lupus is not well understood. It has been suggested that a drug may interact chemically with self molecules to enhance the immunogenic susceptibility of self antigens and also that these drugs or their metabolites may alter the functioning of immune active cells.²⁵ It has been shown in vitro and in vivo that the binding of specific antinuclear antibodies to the surface of keratinocytes is accentuated by exposure to UV light. This same antibody system is highly associated with photosensitive lupus erythematosus syndromes,³⁰ suggesting that photoactive drugs may be syner-

gistic with these antibodies in producing the cutaneous lesions of subacute cutaneous lupus erythematosus.³¹

METHODS FOR IDENTIFYING PHOTSENSITIVITY OF DRUGS

To date, no single method of assaying drug photosensitivity has emerged as the ideal yardstick for establishing photosensitivity. A panel of in vitro and in vivo assay systems has been established for studying photosensitivity reactions, which taken together have proven useful either to predict or to confirm the photosensitizing hazards of a new compound.^{17,32}

In vitro methods used in preliminary screening for photosensitivity include measurement of UV and visible light absorption spectra of the drug; quantification of its ability to photo-oxidize histidine, to induce photohemolysis, and to inhibit yeast growth and mitogen-induced lymphocytic blast transformation; testing on skin equivalents; mutagenicity testing on different organisms and strains; and ability to bind to a protein carrier, such as serum albumin.³² Once the photosensitizing potential has been confirmed through these screening tests, sophisticated in vitro methods may be applied to explore the possible photosensitivity mechanisms and pathways through measurement of triplet excited state, production of excited singlet state oxygen,^{32,33} and photodynamic interaction with DNA (DNA strand breaks and conversion of the supercoiled closed circular form of plasmid DNA to the open circular form).³⁴ While the photosensitizing action of drugs depends on factors that could not be reproduced in vitro, such as those governing penetration and localization of topical agents in the skin, as well as absorption, metabolism, distribution, and excretion of systemic drugs, several animal models are used to assess a photosensitizer's potency in vivo. Hairless mouse skin, guinea pig, albino mice, and rat auricular skin and retina are most commonly used for experimentally reproducing human skin response to drugs and UV exposure.^{19,22,35}

Under clinical conditions, the epidemiological data and clinical features are usually conclusive enough

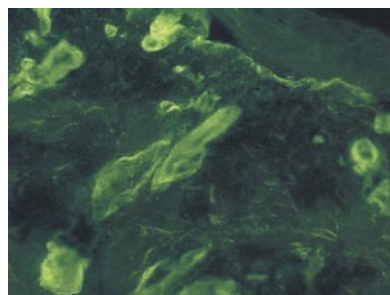


Figure 3. Direct immunofluorescence staining in pseudoporphyria: immune deposits at the dermal-epidermal junction and around dermal blood vessels.

for the diagnosis of a photosensitivity drug eruption. Histological findings can be hardly decisive in differentiating phototoxic from photoallergic reactions, but they may be relevant for the diagnosis of lichenoid eruptions, porphyria cutanea tarda, and pseudoporphyria from other (idiopathic) photosensitivity disorders. In porphyria cutanea tarda and pseudoporphyria, the direct immunofluorescence testing reveals a characteristic deposition of IgG at the basement membrane zone and around dermal blood vessels (**Figure 3**).³⁶

A provisional diagnosis of photoallergic contact is confirmed by the technique of photopatch testing, in which the photosensitizing drug is simultaneously applied at 2 sites, 1 of which is subsequently irradiated. A number of standard photopatch test series exist for screening chemically induced photoallergy.³⁷

PHOTOSENSITIVITY REACTIONS TO ANTIMICROBIAL DRUGS

The ability to cause photosensitivity reactions is a common adverse effect of several anti-infective agents and their derivatives. Most of them are cyclic and tricyclic hydrocarbons, frequently containing an alternative double-bond isoprene or naphthyridine nucleus.¹³ Both phototoxic and photoallergic reactions are reported (**Table 2**).

Topical Antimicrobials

The halogenated salicylanilide derivatives tetrachlorosalicylanilide; 3,4',5-tribromosalicylanilide; 4',5-dibromosalicylanilide; and the antifungal bromochlorosalicylanilide

Table 2. Photoactive Antimicrobials*

Drug	Action Spectrum
Topical antimicrobials†	
Clioquinol	Unknown
Halogenated salicylanilides‡	UV-A
Sulfonamides	UV-B
Olaquinox	UV-A, UV-B
Topical antifungals	
Jadit	UV-A
Multifungin	UV-A
Fentichlor	UV-A
Antibiotics†	
Tetracyclines	UV-A
Fluoroquinolones	UV-A
Nalidixic acid	UV-A
Ceftazidime	Unknown
Griseofulvin	UV-A
Ketoconazole	Unknown
Trimethoprim	Unknown
Sulfonamides	UV-B

*Data in this table from Gould et al.²⁶

†Topical antimicrobials are photoallergens, and antibiotics are phototoxins.

‡Halogenated salicylanilides may have UV-B as an action spectrum.

incorporated as germicides and deodorants in soaps and other toiletries are typical examples of topical photosensitizers. The epidemic incidence of photocontact allergic dermatitis and persistent light eruption they caused in the 1960s rapidly led to their withdrawal from the market in most countries. Other related topical antimicrobials, such as carbanilide derivatives hexachlorophene and 3,4,4'-trichlorocarbanilide (triclocarban), actually used as topical antiseptics have also been implicated as causes of photocontact allergic dermatitis.²⁰

Cases of phototoxic reactions have been recently described in conjunction with some cosmetic, antiseptic, and spermicidal preparations (eg, hexomédine) containing the non-ionic surfactants nonoxynol 9 and 10.³⁸ Local antiseptics containing sulfacetamide and sulfadiazine are also frequent photosensitizers that should be used with caution during summer months.³⁹

We (S.G.V. and G.M.) recently observed a case of photoallergic contact dermatitis in a patient treated for a venous leg ulcer with a preparation containing chloramphenicol and coagulase (**Figure 4**).

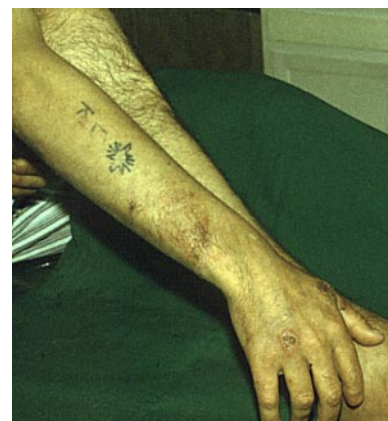

Figure 4. Photoallergic contact dermatitis on the dorsal forearm in a patient treated locally with preparation containing chloramphenicol and coagulase for a venous ulcer.

Sulfonamide Derivatives

Since 1939 when Epstein⁴⁰ first reported photoallergic contact dermatitis following intradermal injection of sulfanilamide, sulfa-derived drugs, including sulfonamide antibacterials, hypoglycemics, and diuretics, have been well-known causes of photosensitivity reactions. The action spectrum of sulfonamides lies within the UV-B range and, to a lesser extent, in the UV-A wavelengths.¹⁷ Photoallergic and, less frequently, phototoxic reactions are common adverse effects seen among patients treated with sulfacetamide, sulfadiazine, sulfaguanidine, and sulfapyridine.

A case of phototoxic eruption progressing to Stevens-Johnson syndrome was recently reported⁴¹ after prophylactic ingestion of the antimalarial combination product containing chloroquine and sulfadoxine-pyrimethamine (Fansidar), the latter component being incriminated as the cause of this unusual adverse reaction.

Other sulfonamides, such as sulfamethoxazole and the trimethoprim-sulfamethoxazole combination, although known to induce Stevens-Johnson syndrome and toxic epidermal necrolysis, are relatively safe in regard to photosensitivity. Sulfasalazine (salazopyrin), used in the treatment of rheumatoid arthritis, chronic bowel disease, and other inflammatory diseases, is reported to produce a diffuse hyperpigmentation of the skin in light-exposed areas.^{42,43}

Dapsone (formerly diaminodiphenylsulfone), a sulfone antibac-

terial known for years for its anti-lepromatous action and currently prescribed in the treatment of several noninfectious dermatoses, was identified in the 1980s as causing photosensitivity. Six cases of presumably phototoxic dermatitis were reported from India among patients with leprosy who were treated for 2 to 9 months with dapsone in a standard dosage of 100 mg/d.⁴⁴

Sulfonamides should be also considered among drugs capable of exacerbating preexisting hepatic porphyrias and inducing sporadic porphyria cutanea tarda. Several cases of drug-induced porphyria cutanea tarda have been reported in association with the sulfonyleurea hypoglycemic drugs tolbutamide and chlorpropamide, which are chemically related to sulfonamide compounds.^{17,45}

Griseofulvin

For many years, griseofulvin has been persistently listed among the systemic photosensitizing drugs. The precise mechanisms of the various photosensitivity reactions it causes are not completely clarified; however, UV-A radiation is responsible for eliciting griseofulvin photosensitivity.

In animal models, griseofulvin in high doses interferes with porphyrin metabolism to cause phototoxic reactions. In humans, griseofulvin has been shown to inhibit heme synthesis, which results in increased urinary porphyrin excretion and appearance of acute hepatic porphyrias, especially in susceptible individuals.⁴⁶⁻⁴⁸ Griseofulvin is known to exacerbate a preexisting systemic lupus erythematosus or unmask a lupus diathesis. There are also reports of cases of subacute cutaneous lupus erythematosus induction by oral administration of griseofulvin.³¹

Tetracyclines

Tetracycline antibiotics serve as an excellent example of the phototoxic hazards of antibacterial agents. Among them, chlorderivatives are most frequently reported to cause phototoxicity.^{9,49,50} Chlortetracycline and doxycycline are more photoactive than tetracycline, oxytetracycline, methacycline, or minocycline. In one study,⁵¹ doxy-

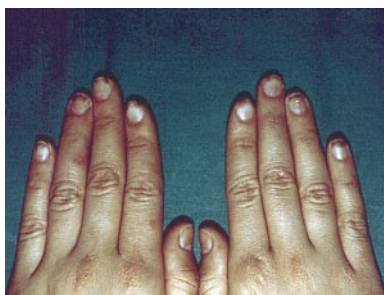

Figure 5. Tetracycline-induced chromonychia: brown-gray discoloration of the distal portion of several nail plates.

cycline (200 mg/d) was compared with minocycline (200 mg/d), and phototoxic reactions were noted in 11 of 15 subjects and 0 of 17 subjects, respectively. In a double-blind crossover study with doxycycline (100 mg twice daily), lymecycline (600 mg twice daily), and placebo, run-in combination with UV-A radiation in a series of 15 healthy volunteers, doxycycline was found to have greater phototoxic potency than lymecycline (which is available abroad). The phototoxic reaction was dependent on the dose of doxycycline and the UV-A intensity. Bjellerup and Ljunggren⁵² recommend that therapy with doxycycline be avoided during summertime and in sunny climates.

There are differences in the phototoxic potential of tetracycline derivatives *in vitro* as well.⁴⁶ In an assay of the UV-A-induced hemolysis of human red blood cells in the presence of 8 commercial tetracyclines, the extent of cells undergoing hemolysis was 85% for doxycycline (50 µg/mL; UV-A, 72 J/cm²), 36% for methacycline (200 µg/mL), and only 18% for tetracycline, oxytetracycline, and chlortetracycline (200 µg/mL). Minocycline did not show hemolytic effect.⁵³

Common clinical manifestations of tetracycline photosensitivity include sunburn, sometimes with blistering, papular eruption, or both.⁹ Marked residual pigmentation is frequently observed. Photoonycholysis is a common feature with many tetracyclines, occurring 3 to 6 weeks after drug administration on the distal portion of 1 or several nails. In addition, chromonychia with white, yellow, or brown discoloration of nail plates may be observed (**Figure 5**).

Tetracycline and oxytetracycline have also been reported to cause pseudoporphyria, which manifests with skin fragility, traumatic bullae, scarring and milia formation on sun-exposed areas, and normal porphyrin levels. The effective wavelengths for eliciting photoreactivity fall in the long UV-A and short visible range (320-425 nm). Clinical phototoxicity, the rates of photochemical degradation, and the *in vitro* phototoxicity of the tetracyclines are qualitatively correlated.⁹

The precise mechanisms of tetracycline phototoxicity are not fully understood. *In vitro* studies have shown that they are dependent on oxygen and complement. The chromophores in the skin are cell membranes, ribosomal proteins, and DNA.^{9,54} Two major types of damage induced in DNA molecules by the photosensitizing activity of tetracycline derivatives are proposed; these are alteration of guanine residues and breakage of the sugar-phosphate backbone.⁵⁴

Quinolones

The first quinolone drug, nalidixic acid, was introduced as a uroantiseptic in 1962. Shortly thereafter, a high incidence of photosensitivity reactions was noted among patients treated with nalidixic acid,⁵⁵ followed by the description of a UV-A-enhanced photocarcinogenesis in hairless mice.⁶ Pipemidic acid, oxolinic acid, and rosoxacin, which belong to the same quinolone generation, demonstrated similar photosensitizing properties.¹⁸ Currently, the therapeutic use of these quinolone derivatives is limited, although they are still marketed in several countries in Europe. The most frequently reported photosensitive effects of the first-generation quinolones included systemic, often bullous, phototoxic eruptions; porphyria cutanea tarda; and pseudoporphyria.

In recent years, the introduction of new fluoroquinolone derivatives raised a great deal of expectation related to greater efficacy at smaller dosages, convenient administration once to twice daily, and diminished toxicity.^{10,56} Since the mid-

1980s, several fluoroquinolones have been marketed worldwide, including ciprofloxacin, ofloxacin, norfloxacin, pefloxacin, lomefloxacin, temafloxacin, fleroxacin, enoxacin, tosufloxacin, and sparfloxacin. It has become, however, increasingly clear that new fluoroquinolones still exhibit varying degrees of photosensitizing activity.²² For the most part, they produce phototoxic reactions, although there are a few reports of photoallergy as well. Most of the photoallergic reactions are reported among patients treated with enoxacin²² and characterized by eczematous clinical and histological features, a prolonged induction period after first administration, and a dose-independent reproducible response.⁵⁷ Three cases of photoallergic reactions to lomefloxacin were reported after confirmation by positive results to scarified photopatch tests.⁵⁸ A prolonged lichenoid eruption is observed in some patients treated with sparfloxacin, but photoallergy has not been confirmed with this drug.¹⁹ A severe generalized febrile subcorneal pustular eruption has been reported in a patient treated with norfloxacin.⁵⁹ Photo-onycholysis is an occasional adverse effect of treatment with fluoroquinolones.^{60,61}

Clinical and epidemiological studies encompassing all fluoroquinolone compounds are not available. But, empirical studies have suggested pefloxacin and fleroxacin as the most potent photosensitizers, while enoxacin, norfloxacin, and ofloxacin are less potent. Comparing the phototoxic histological changes of mouse ear skin occurring following systemic administration of quinolones and UV-A exposure, sparfloxacin given in doses of 50 or 100 mg/kg induced responses similar to those of enoxacin and levofloxacin at doses of 400 and 800 mg/kg.²⁷ In BALB/c mice, the estimated dose-related relative risk of phototoxicity was 1.3:17:19:21 for levofloxacin:ciprofloxacin:ofloxacin:enoxacin:lomefloxacin.¹² With lomefloxacin and sparfloxacin, relatively high frequencies of phototoxic reactions have been reported, although both compounds are about 10 times less phototoxic than nalidixic acid.^{19,22} Phototoxic ef-

fects of quinolones are strictly dose dependent as has been shown in clinical studies comparing patients receiving different dosages of fleroxacin, ie, 800, 600, or 400 mg daily taken orally, with no phototoxic reactions associated with the 400-mg dose.²²

Several other factors contribute to the incidence and intensity of quinolone phototoxicity. Compounds with longer half-life or greater bioavailability seem to be more phototoxic than the rapidly metabolized formulations. Substitution of a methoxy group at the 8 position of the quinolone nucleus may also reduce phototoxicity.⁶² Quinolone photosensitivity is mainly activated by UV-A wavelengths, with the exception of fleroxacin, which is most active in vitro in the UV-B range.^{18,22} A synergistic effect of UV-B and UV-A has been documented in sparfloxacin-induced phototoxic ear-swelling response in mice.¹⁹

The mechanism of quinolone phototoxicity involves a transfer of energy from the photoexcited chromophore to molecular oxygen, generating active oxygen species, mainly free hydroxy radicals.¹³ In vitro induction of DNA strand-breaking activity has been shown for tosufloxacin, enoxacin,³⁴ and sparfloxacin¹⁹ present in small amounts (50 μ mol, 2 μ mol, and 10 μ mol, respectively) in the assay system. The use of singlet oxygen and hydroxy radical scavengers (allopurinol, soybean trypsin inhibitor, β -carotene) may be protective against the phototoxic effects of quinolones. On the other hand, the in vitro capability of several quinolones to act as a peroxide to unsaturated lipid squalene in ethanol solution suggests that the nonsinglet oxygen mechanism is operative in addition to the singlet oxygen mechanism.⁶³

MANAGEMENT OF ANTIMICROBIAL PHOTOSENSITIVITY

Photosensitization of the skin by several groups of antimicrobial agents is a problem that is increasingly attracting attention. It is still anticipated that the ideal antimicrobial drug providing appropriate bacterial coverage in a dose

too small to cause photosensitivity will be found among tetracyclines and fluoroquinolones.

If the photosensitizing effect of a drug is known before patient exposure, appropriate clinical management might control the incidence of photosensitivity adverse reactions. Avoidance of direct sunlight and sun-tanning facilities, use of protective clothing and appropriate UV-A and UV-B sunscreens,¹³ and evening dosing strategy⁶⁴ are factors that can minimize the risk of photosensitivity effects of most antimicrobials.

Accepted for publication February 12, 1998.

Reprints: Lawrence Charles Parish, MD, 1819 John F. Kennedy Blvd, Suite 465, Philadelphia, PA 19103 (e-mail: parish2@jeflin.tju.edu).

REFERENCES

- Hakim RE. Rediscovery of a treatment for vitiligo. *Clio Med.* 1969;4:277-289.
- Hudson JB. Plant photosensitizers with antiviral properties. *Antiviral Res.* 1989;12:55-74.
- Hudson JB, Graham EA, Harris L, et al. The unusual UVA-dependent antiviral properties of the furocoumarin, coriandrin. *Photochem Photobiol.* 1993;57:491-496.
- Hudson JB, Zhou J, Chen J, et al. Hypocrellin, from *Hypocrella babuase*, is phototoxic to human immunodeficiency virus. *Photochem Photobiol.* 1994;60:253-255.
- Fabbri P, Panconesi E. Erythramultiforme ("minus" and "maius") and drug intake. *Clin Dermatol.* 1993;4:479-489.
- Baes H. Photosensitivity caused by nalidixic acid. *Dermatologica.* 1968;136:61-64.
- Orentreich N, Harber LC, Tromovitch TA. Photosensitivity and photo-onycholysis due to demethylchlortetracycline. *Arch Dermatol.* 1961;83:68-75.
- Blank H, Cullen S, Catalano PM. Photosensitivity studies with demethylchlortetracycline and doxycycline. *Arch Dermatol.* 1968;97:1-2.
- Hasan T, Kochevar E, McAuliff DJ, et al. Mechanism of tetracycline phototoxicity. *J Invest Dermatol.* 1984;83:179-183.
- Stahlmann R. Safety profile of the quinolones. *J Antimicrob Chemother.* 1990;20(suppl D):31-44.
- Bowie WB, Willetts V, Jewesson PJ. Adverse reactions in a dose-ranging study with a new long-acting fluoroquinolone, fleroxacin. *Antimicrob Agents Chemother.* 1989;33:1778-1782.
- Norrby SR, Lietman PS. Safety and tolerability of fluoroquinolones. *Drugs.* 1993;45(suppl 3):59-64.
- González E, González S. Drug photosensitivity, idiopathic photodermatoses, and sunscreens. *J Am Acad Dermatol.* 1996;35:871-885.
- Epstein JH. Phototoxicity and photoallergy in man. *J Am Acad Dermatol.* 1983;8:141-147.
- Warin AP. The ultraviolet erythemas in man. *Br J Dermatol.* 1978;98:473-477.
- Harber LC, Baer RL. Pathogenic mechanisms of drug-induced photosensitivity. *J Invest Dermatol.* 1972;58:327-342.

17. Ljunggren B, Bjellerup M. Systemic drug photosensitivity. *Photodermatology*. 1986;3:26-35.
18. Przybilla B, Georgii A, Bergner T, et al. Demonstration of quinolone phototoxicity in vitro. *Dermatologica*. 1990;181:98-103.
19. Tokura Y, Iwamoto Y, Mizutani K, et al. Sparfloxacin phototoxicity: potential photoaugmentation by ultraviolet A and B sources. *Arch Dermatol Res*. 1996;288:45-50.
20. Emmett EA. Drug photoallergy. *Int J Dermatol*. 1978;17:370-379.
21. DeLeo VA, Maso MJ. Photosensitivity. In: Moschella SL, Hurley HJ, eds. *Dermatology*. Philadelphia, Pa: WB Saunders Co; 1992:507-531.
22. Mirensky YM, Parish LC. Photosensitivity and the quinolones. *J Eur Acad Dermatol Venereol*. 1995;4:1-4.
23. Toback AC, Longley J, Cardullo AC, Doddy U, Romagnoli M, DeLeo VA. Severe chronic photosensitivity in association with acquired immunodeficiency syndrome. *J Am Acad Dermatol*. 1986;15:1056-1057.
24. Rich MW. Drug-induced lupus. *Postgrad Med*. 1996;100:299-302.
25. Cush JJ, Goldings EA. Drug-induced lupus: clinical spectrum and pathogenesis. *Med Sci*. 1985;290:36-45.
26. Gould JW, Mercurio MG, Elmets CA. Cutaneous photosensitivity diseases induced by exogenous agents. *J Am Acad Dermatol*. 1995;33:551-573.
27. Alarcón-Segovia D, Kraus A. Drug-related lupus syndromes and their relationship to spontaneously occurring systemic lupus erythematosus. *Clin Rheumatol Int Pract Res*. 1991;5:1-12.
28. Shapiro LE, Knowles SR, Shear NH. Comparative safety of tetracycline, minocycline, and doxycycline. *Arch Dermatol*. 1997;133:1224-1230.
29. Laversuch CJ, Collins DA, Charles PJ, Bourke BE. Sulphasalazine-induced autoimmune abnormalities in patients with rheumatic disease. *Br J Rheumatol*. 1995;34:435-439.
30. Norris DA, Lee LA. Antibody-dependent cytotoxicity and skin disease. *J Invest Dermatol*. 1985;85:165S-175S.
31. Miyagawa S, Okuchi T, Shiomi Y, Sakamoto K. Subacute cutaneous lupus erythematosus lesions precipitated by griseofulvin. *J Am Acad Dermatol*. 1989;21:343-346.
32. Arlett C, Earl L, Ferguson J, et al. British Photodermatology Group Workshop: predictive in vitro methods for identifying photosensitizing drugs: a report. *Br J Dermatol*. 1995;132:271-274.
33. Navaratnam S, Parsons BJ, Hughes JL. Laser-flash photolysis studies of benoxaprofen and its analogues. 1: yields of triplet states and singlet oxygen in acetonitrile solutions. *J Photochem Photobiol A*. 1993;73:97-103.
34. Iwamoto Y, Kurita A, Shimizu T, et al. DNA strand-breaking activities of quinolone antimicrobial agents under visible light irradiation. *Biol Pharm Bull*. 1994;17:654-657.
35. Shimoda K, Yoshida M, Wagai N, et al. Phototoxic lesions induced by quinolone antibacterial agents in auricular skin and retina of albino mice. *Toxicol Pathol*. 1993;21:554-561.
36. Vassileva S, Prost C. Discovering vesiculobullous drug eruptions through dermatopathologic techniques. *Clin Dermatol*. 1993;11:557-565.
37. Fotiades J, Soter NA, Lim HW. Results of evaluation of 203 patients for photosensitivity in a 7.3-year period. *J Am Acad Dermatol*. 1995;33:597-602.
38. Michel M, Dompartin A, Moreau A, Leroy D. Contact photosensitivity to nonoxynol used in antiseptic preparations. *Photodermatol Photoimmunol Photomed*. 1994;10:198-201.
39. Bork K. *Cutaneous Side Effects of Drugs*. Philadelphia, Pa: WB Saunders Co; 1981:338-361.
40. Epstein S. Photoallergy and primary sensitivity to sulfanilamide. *J Invest Dermatol*. 1939;2:43-51.
41. Ortel B, Sivayathorn A, Honigsman H. An unusual combination of phototoxicity and Stevens-Johnson syndrome due to antimalarial therapy. *Dermatologica*. 1989;178:39-42.
42. Gabazza EC, Taguchi O, Yamakami T, et al. Pulmonary infiltrates and skin pigmentation associated with sulfasalazine. *Am J Gastroenterol*. 1992;87:1654-1657.
43. Veale DJ, Morley KD. Sulphasalazine-induced lupus in psoriatic arthritis. *Br J Rheumatol*. 1995;34:383-384.
44. Dhanapaul S. DDS-induced photosensitivity with reference to six case reports. *Lepr Rev*. 1989;60:147-150.
45. Lim HW, Belsito DV. Basic photobiology, phototoxicity, and photoallergy. In: Arndt KA, Leboit PE, Robinson JK, Wintroub BU, eds. *Cutaneous Medicine and Surgery*. Vol 1. Philadelphia, Pa: WB Saunders Co; 1997:725-731.
46. Targovnik SE, Targovnik JH. Cutaneous drug reactions in porphyrias. *Clin Dermatol*. 1986;4:110-117.
47. Rimington C, Morgan PN, Nicholl K, et al. Griseofulvin administration and porphyrin metabolism: a survey. *Lancet*. 1963;1:312-322.
48. Watson CJ, Lynch F, Bossenmaier I, Cardinal R. Griseofulvin and porphyrin metabolism: special reference to normal fecal porphyrin excretion. *Arch Dermatol*. 1968;98:451-468.
49. Maibach HI, Sams WM Jr, Epstein JH. Screening for drug toxicity by wave lengths greater than 3100 Å. *Arch Dermatol*. 1967;95:12-15.
50. Frost P, Weinstein G, Gomez EC. Methacycline and demeclocycline in relation to sunlight. *JAMA*. 1971;216:326-329.
51. Frost P, Weinstein G, Gomez EC. Phototoxic potential of minocycline and doxycycline. *Arch Dermatol*. 1972;105:681-683.
52. Bjellerup M, Ljunggren B. Differences in phototoxic potency should be considered when tetracyclines are prescribed during summertime: a study on doxycycline and lymecycline in human volunteers, using an objective method for recording erythema. *Br J Dermatol*. 1994;130:356-360.
53. Bjellerup M, Ljunggren B. Photohemolytic potency of tetracyclines. *J Invest Dermatol*. 1985;84:262-264.
54. Piette J, Decuyper J, van de Vorst A. DNA alterations photosensitized by tetracycline and some of its derivatives. *J Invest Dermatol*. 1986;86:653-658.
55. Ramsay CA, Obreshkova E. Photosensitivity from nalidixic acid. *Br J Dermatol*. 1974;91:523-528.
56. Wolfson JS, Hooper PC. Fluoroquinolone antimicrobial agents. *Clin Microbiol Rev*. 1989;2:378-424.
57. Kawabe Y, Mizuno N, Shigeru S. Photoallergic reaction caused by enoxacin. *Photodermatology*. 1989;6:58-60.
58. Kurumaji Y, Shono M. Scarified photopatch testing in lomefloxacin photosensitivity. *Contact Dermatitis*. 1992;26:5-10.
59. Shelley ED, Shelley WB. The subcorneal pustular drug eruption: an example induced by norfloxacin. *Cutis*. 1988;42:24-27.
60. Baran R, Brun P. Photoonycholysis induced by the fluoroquinolones pefloxacin and ofloxacin: report on 2 cases. *Dermatologica*. 1986;173:185-188.
61. Baran R, Juhlin L. Drug-induced photo-onycholysis: three subtypes identified in a study of 15 cases. *J Am Acad Dermatol*. 1987;17:1012-1016.
62. Marutani K, Matsumoto M, Otabe Y, et al. Reduced phototoxicity of a fluoroquinolone antibacterial agent with a methoxy group at the 8 position in mice irradiated with long-wavelength UV light. *Antimicrob Agents Chemother*. 1993;37:2217-2223.
63. Fujita H, Matsuo I. In vitro phototoxic activities of new quinolone antibacterial agents: lipid peroxidative potentials. *Photodermatol Photoimmunol Photomed*. 1994;10:202-205.
64. Lowe NJ, Fakouhi TD, Stern RS, et al. Photoreactions with a fluoroquinolone antimicrobial: evening versus morning dosing. *Clin Pharmacol Ther*. 1994;56:587-591.