

Midterm Prognosis of Patients With Suspected Coronary Artery Disease and Normal Multislice Computed Tomographic Findings

A Prospective Management Outcome Study

Martine Gilard, MD; Grégoire Le Gal, MD; Jean-Christophe Cornily, MD; Ulrich Vinsonneau, MD; Cédric Joret, MD; Pierre-Yves Pennec, MD; Jacques Mansourati, MD; Jacques Boschat, MD

Background: The gold standard test for the diagnosis of coronary artery disease (CAD) is conventional coronary angiography (C-CAG). Lately, multislice computed tomographic coronary angiography (MSCT-CAG) demonstrated a high sensitivity and a negative predictive value for a CAD primary diagnosis when compared with C-CAG. The aim of our study is to prospectively assess the safety of ruling out CAD based solely on a normal MSCT-CAG result.

Methods: From June 15, 2004, to January 20, 2006, consecutive patients initially scheduled for C-CAG for a primary diagnosis of CAD underwent MSCT-CAG instead. Patients with a highly calcified coronary network or with an abnormal or a noninterpretable MSCT-CAG result underwent secondary C-CAG and were excluded from the study. We included patients whose diagnosis of CAD was ruled out by a normal MSCT-CAG result; in those patients, C-CAG was not performed. All patients under-

went further follow-up with clinical end points (death, subsequent C-CAG, and myocardial infarction).

Results: In 141 patients, MSCT-CAG results were considered normal. During the follow-up period (mean, 14.7 months), those patients experienced 0% mortality, a 3.5% rate of subsequent C-CAG, and a 0.7% rate of myocardial infarction. The risks of subsequent death, new referral for C-CAG, or coronary events compare favorably with those following normal C-CAG, which were 0.4%, 4.3%, and 0.6%, respectively.

Conclusions: Multislice computed tomographic CAG safely rules out CAD in patients with suspected disease and allows patients to be managed less invasively, by reducing the number in whom C-CAG has to be performed.

Arch Intern Med. 2007;165(15):1686-1689

CORONARY ARTERY DISEASE (CAD) remains the leading cause of death in the Western world. The gold standard test for the diagnosis of CAD is conventional coronary angiography (C-CAG). Because of its enhanced spatial and temporal resolution, multislice computed tomography (MSCT) improves small-structure visualization. In recent years, its diagnostic performance in the assessment of CAD has been compared with C-CAG in studies in which all patients with suspected CAD underwent C-CAG and MSCT-CAG. High sensitivity and negative predictive values of as much as 96% to 99% were obtained with 8-, 16-, and 64-slice MSCT-CAG.¹⁻⁵ This high negative predictive value suggests a potentially important role for MSCT-CAG in reliably ruling out significant lesions, but, to our knowledge, no prospective study has ever evaluated MSCT-CAG and the occurrence of midterm follow-up clinical events. The result of

C-CAG—an invasive and expensive test^{6,7}—is sometimes negative, and the use of MSCT-CAG might avoid many C-CAGs and be highly cost-effective. However, before its implementation can be recommended in CAD diagnostic strategies, its accuracy needs to be assessed in management outcome studies, in which diagnosis and therapeutic strategy would be decided based on MSCT-CAG alone, without reference to any C-CAG results. The objective of the present study was to assess the safety of ruling out CAD based solely on a normal MSCT-CAG result.

METHODS

PATIENTS

From June 15, 2004, to January 20, 2006, all consecutive patients scheduled for C-CAG for a primary diagnosis of CAD, with either typical chest pain but noncontributive functional test results (electrocardiographic exercise test) or no symptoms but positive functional test re-

Author Affiliations: Department of Cardiology (Drs Gilard, Cornily, Vinsonneau, Joret, Pennec, Mansourati, and Boschat) and Division EA3878, Department of Internal Medicine and Chest Diseases (Dr Le Gal), Brest University Hospital, Brest, France.

sults, were considered for inclusion. Symptomatic patients were placed into 3 categories. The exclusion criteria comprised known CAD, acute coronary syndrome, C-CAG ordered for preoperative assessment, dilated cardiomyopathy, irregular heart rate, contraindications for iodinated contrast agents, and renal insufficiency. Informed consent was obtained from all patients.

DIAGNOSIS WORKUP

At admission, a standardized data collection form was filled out by the duty physician (M.G., J.-C.C., or P.-Y.P.). Demographic information, CAD risk factors, and clinical signs were collected. All patients underwent MSCT-CAG. Before iodinated contrast agent injection, a native scan was performed to assess coronary calcification, using a scoring method analogous to that of Agatston et al.⁸ A calcified lesion was defined as an area of 3 connected pixels or greater (>130 Hounsfield units), expressed as an Agatston score equivalent (ASE). An ASE cutoff of 1000 was chosen as the best compromise between avoiding MSCT-CAG scans that would be noninterpretable because of calcification and maximizing the number of patients in whom MSCT-CAG alone could rule out CAD.⁹ Thus, patients with an ASE of 1000 or greater did not receive iodinated contrast injection and directly underwent C-CAG on the same day. Patients with an ASE of less than 1000 underwent MSCT-CAG. When the result of MSCT-CAG was either inconclusive (for technical reasons, mainly artifacts) or positive, patients underwent C-CAG 24 hours later for diagnostic confirmation and/or percutaneous coronary intervention, and were excluded from the study. Patients with a normal MSCT-CAG result did not undergo C-CAG and were finally considered for inclusion. We defined normal patients as those with either nonobstructive CAD (<50% luminal narrowing by visual assessment) or no calcifications or atherosclerotic plaques.

MSCT-CAG Protocol and Image Reconstruction

The MSCT-CAG data sets were acquired using a 16-slice MSCT-CAG scanner (MX 8000 IDT 16; Philips, Eindhoven, the Netherlands). Briefly, a native scan without contrast medium was performed to determine total coronary and aortic valve calcium levels. Then, a volume data set was acquired (16.00 × 0.75-mm cross section; gantry rotation time, 420 milliseconds; and table feed, 2.8 mm per rotation), covering the distance from the carina to the diaphragmatic side of the heart. Tube current was 400 mA, with a tube voltage of 120 kV. The entire heart was scanned during a single breath-hold; 120 mL of contrast agent (Xenetix 350; Guerbet, Aulnay sous Bois, France) was continuously injected at a rate of 4 mL/s. Automated detection of peak enhancement in the aortic root was used to time the scan. Patients with a heart rate of more than 70/min received additional intravenous β-blocker (5 mg of atenolol).

Cross-sectional images were reconstructed with a slice thickness of 0.8 mm at 0.4-mm intervals, with retrospective gating, to obtain an image acquisition window of 100 milliseconds. Axial images at 0%, 20%, 30%, 40%, 50%, 65%, 75%, and 85% of the relative risk interval were reconstructed for each patient, and analyzed for motion artifacts.

All data sets were independently analyzed by physicians experienced in MSCT-CAG (M.G., J.-C.C., and P.-Y.P.), using multiplanar reformation and 3-dimensional reconstruction by the "volume rendering" technique.

Follow-up

All patients were followed up for a minimum of 6 months by their usual cardiologist and family physician. One of the study

Table. Characteristics of the 141 Patients

Characteristic	Value ^a
Male sex, No. (%)	88 (62.4)
Weight, kg ^b	76.0 ± 16.8
Creatinine clearance, mL/min/1.73 m ^{2b}	78.5 ± 14.8
Age, y ^b	59 ± 12
Smoker	42.5
Dyslipidemia	51.5
Diabetes mellitus	13.5
Hypertension	50.3
Family history of coronary artery disease	20.1
β-Blocker use before MSCT-CAG	52.2
Intravenous β-blocker use	15.3

Abbreviation: MSCT, multislice computed tomographic coronary angiography.

SI conversion factor: To convert creatinine clearance to milliliters per second per square meters, multiply by 0.0167.

^aData are given as percentage of patients unless otherwise indicated.

^bData are given as mean ± SD.

investigators (M.G., U.V., or C.J.) called each patient on the telephone to discuss symptoms, the occurrence of new events (myocardial infarction, heart failure, and evolution of angina pectoris), any change in cardiac medication, hospital admission, and repeated C-CAG.

STATISTICAL ANALYSIS

General characteristics, CAD risk factors, and clinical signs are expressed as means and SDs for continuous variables and as percentages for qualitative variables. The rates of coronary events, death, and repeated C-CAG during follow-up are assessed with their respective 95% confidence intervals (CIs).

RESULTS

During the study, 200 patients were initially considered for inclusion. All 200 patients underwent MSCT-CAG without complication. Eighteen patients (9.0%) with ASEs of 1000 or greater did not undergo opacification, underwent C-CAG on the same day, and were excluded from the study. Contrast-enhancement MSCT-CAG was performed on the 182 remaining patients. Of these patients, 41 also underwent C-CAG (4 because of inconclusive MSCT-CAG results and 37 because MSCT-CAG showed evidence of CAD). These 41 patients were also excluded from the study. Finally, 141 patients with a normal MSCT-CAG result were included in the study, did not undergo C-CAG, and were followed up. Patient characteristics are summarized in the **Table**, and the study flowchart is presented in the **Figure**.

INDICATIONS FOR MSCT-CAG

Thus, 141 patients were considered to have no significant coronary stenosis and did not undergo C-CAG. The indications for the MSCT-CAG scans were as follows: in the 115 patients (81.6%) with chest pain, they included angina pectoris and a negative exercise test result (58 patients [41.1%]), atypical angina pectoris and a positive exercise test result (28 patients [19.9%]), and angina pec-

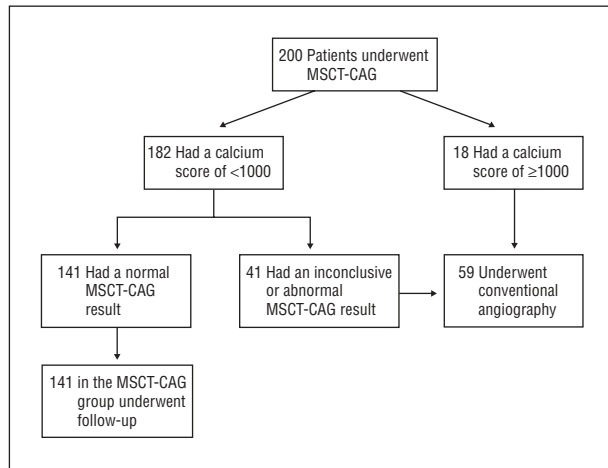


Figure. Patient management flowchart. MSCT indicates multislice computed tomographic coronary angiography.

toris and more than 2 risk factors without an exercise test (29 patients [20.6%]); and in the 26 patients (18.4%) with suspected silent myocardial ischemia, they included a positive exercise test result without angina pectoris (24 patients [17.0%]) and more than 2 risk factors and a left bundle branch block (2 patients [1.4%]).

FOLLOW-UP

The mean follow-up was 14.7 months (range, 6-26 months), with no patient lost to follow-up. No patient died during follow-up (0 of 141 patients [0%]; 95% CI, 0%-2.7%). Of the 141 patients, 5 (3.5%; 95% CI, 1.5%-8.0%) underwent C-CAG during follow-up for recurrence or worsening of chest pain, all more than 7 months after initial MSCT-CAG (range, 8-11 months). Of these 5 patients, 3 had a significant lesion: 1 in the mid-left anterior descending coronary artery, 1 in the distal segment of the right coronary artery, and 1 in the circumflex artery. The C-CAG result was normal in the other 2 patients, confirming MSCT-CAG findings. Finally, 1 patient experienced myocardial infarction 19 months after initial diagnostic MSCT-CAG (1 of 141 patients [0.7%]; 95% CI, 0.1%-3.9%). We retrospectively reviewed images of these false-negative MSCT-CAG results. Two lesions matched to calcified areas that had been observed on MSCT-CAG and that were considered nonsignificant on left anterior descending coronary and circumflex arteries (ASEs were 175 and 723, respectively). A stenosis of the right coronary artery was found at this second reading for the third patient. The patient who developed a secondary myocardial infarction had an occlusion of the left anterior descending coronary artery on C-CAG at the time of the myocardial infarction. Careful review of this patient's baseline MSCT-CAG failed to find any significant left anterior descending coronary artery lesion. There was no additional patient with unstable angina undergoing follow-up who did not undergo catheterization.

COMMENT

In this prospective management outcome study, 141 patients with suspected CAD in whom this diagnosis was

ruled out solely based on a normal MSCT-CAG result experienced 0% mortality, a 3.5% rate of subsequent CAG, and a 0.7% rate of myocardial infarction during a mean 14.7-month follow-up.

Multislice computed tomography CAG has emerged rapidly because of rapid improvement in imaging technology as a sensitive diagnostic tool. The 16-slice generation of MSCT-CAG demonstrated highly accurate qualitative identification of significant (>50%) coronary artery stenosis in vessels larger than 1.5 to 2.0 mm, with reported sensitivities, specificities, and positive and negative predictive values ranging from 82% to 95%, 82% to 98%, 79% to 83%, and 98% to 99%, respectively.^{2,5,10-13} In a meta-analysis by Schuijff et al,¹⁴ of 24 studies totaling 1300 patients, the overall sensitivity, specificity, and positive and negative predictive values of MSCT-CAG (4-16 slices) were 85% (95% CI, 83%-87%), 95% (95% CI, 93%-95%), 76% (95% CI, 74%-78%), and 97% (95% CI, 97%), respectively. The newest-generation 64-slice MSCT-CAG has improved imaging quality, is nearly motion free, and gives isotropic image quality and data acquired during a single breath-hold of about 13 seconds. These improvements have enhanced sensitivity (range, 94%-99%), specificity (range, 95%-97%), and positive predictive value (range, 76%-97%), although the negative predictive value remains unchanged.^{4,15,16} The high sensitivity and negative predictive value strongly suggest that MSCT-CAG could be useful in ruling out a diagnosis of CAD. However, to our knowledge, no pragmatic management outcome study validating the safety and usefulness of the procedure has been published. In our study, after a mean of 14.7 months of follow-up, 137 of 141 patients (97.2%) were clinically event free. This value can favorably be compared with the high negative predictive value that was validated by all the previous studies^{2,4,5,10-13,15,16} comparing MSCT-CAG with C-CAG. Other noninvasive tests also provide prognostic information useful in risk stratification: a normal single-photon emission computed tomographic result has been shown to indicate a good clinical outcome, with an annual death or infarct rate of less than 1% per year¹⁷; and exercise echocardiography has a 98.8% negative predictive value for myocardial infarction and cardiac death, with at least 3 months of follow-up.¹⁸ These results confirm that MSCT-CAG is useful in the diagnostic workup of patients with suspected significant CAD and can, when the result is normal, safely rule out this diagnosis.

Although the incidence of significant morbidity and mortality is low, C-CAG may cause serious complications. A 1990 survey by the Society for Cardiac Angiography and Interventions⁶ indicated that the total risk of all major complications with C-CAG was 1.70% in 71 916 patients, with a mortality of 0.11%, a myocardial infarction rate of 0.05%, a stroke syndrome rate of 0.07%, and a vascular complication rate of 0.43%. American College of Cardiology/American Heart Association guidelines for C-CAG⁷ recommend performing angiography in patients with stable chest pain and a contraindication to stress testing, a positive stress test result, or a negative stress test result if the diagnosis is still uncertain. Coronary angiography is also recommended in asymptomatic patients with positive ex-

ercise or stress test results. Nevertheless, the rate of normal coronary angiograms in this population is not negligible, exposing patients to the previously cited complications. Our prospective study demonstrates that MSCT-CAG alone can be a cost-effective and safe alternative to C-CAG in this population at high risk but with an intermediate prevalence of CAD.

Multislice computed tomography CAG can safely be used alone to exclude a diagnosis of CAD in patients with suspected disease. The risks of subsequent death, coronary events, and new referral for C-CAG compare favorably with those following negative C-CAG results. Follow-up studies of patients with normal findings on CAG were reviewed by Lichtlen et al¹⁹ in 1995. Excluding the studies with more than 5 years of follow-up, the pooled estimated risks of death, myocardial infarction, and repeated C-CAG in 1093 C-CAG-negative patients were 0.4%, 0.6%, and 4.3%, respectively, compared with 0%, 0.7%, and 3.5%, respectively, in the present study. Most acute coronary syndromes occur by rupture or erosion of "high-risk" plaques that are in more than two-thirds of the cases not significantly stenotic. Moreover, atherosclerotic plaque growth and destabilization are highly variable. Multislice computed tomography CAG, as well as C-CAG, is a pure anatomical test and even if the technique allows some degree of plaque analysis and characterization (which is impossible with C-CAG), the spatial resolution is not high enough for molecular imaging and to assess adequately the plaque disruption risk. Thus, long-term risk prediction is impossible with MSCT-CAG and with C-CAG.

In early 2007, an article published by Pundziute et al²⁰ showed the prognostic value of MSCT-CAG in patients with known or suspected CAD. The researchers found that MSCT-CAG provides independent prognostic information, but the study was not designed to especially assess patients with normal or subnormal MSCT-CAG results. Moreover, MSCT-CAG findings were not included in the diagnostic/therapeutic workup, whereas this was precisely the primary aim of our study.

In conclusion, MSCT-CAG safely rules out suspected CAD and allows patients to be managed less invasively, by reducing the number in whom C-CAG has to be performed.

Accepted for Publication: April 15, 2007.

Correspondence: Martine Gilard, MD, Department of Cardiology, Brest University Hospital, CHU de la Cavale Blanche, Boulevard Tanguy Prigent, 29609 Brest CEDEX, France (Martine.gilard@chu-brest.fr).

Author Contributions: *Study concept and design:* Gilard, Le Gal, Cornily, Vinsonneau, Pennec, Mansourati, and Boschat. *Acquisition of data:* Gilard, Cornily, Vinsonneau, Joret, Pennec, and Boschat. *Analysis and interpretation of data:* Gilard, Le Gal, Cornily, Vinsonneau, Joret, Pennec, and Boschat. *Drafting of the manuscript:* Gilard, Cornily, Vinsonneau, Joret, Pennec, Mansourati, and Boschat. *Critical revision of the manuscript for important intellectual content:* Gilard, Le Gal, Cornily, Vinsonneau, and Bos-

chat. *Statistical analysis:* Gilard and Le Gal. *Obtained funding:* Gilard. *Administrative, technical, and material support:* Gilard and Boschat. *Study supervision:* Gilard, Cornily, Vinsonneau, Joret, Pennec, Mansourati, and Boschat. **Financial Disclosure:** None reported.

REFERENCES

1. Maruyama T, Yoshizumi T, Tamura R, et al. Comparison of visibility and diagnostic capability of noninvasive coronary angiography by eight-slice multidetector-row computed tomography versus conventional coronary angiography. *Am J Cardiol.* 2004;93(5):537-542.
2. Nieman K, Cademartiri F, Lemos PA, Raaijmakers R, Pattynama PM, de Feyter PJ. Reliable noninvasive coronary angiography with fast submillimeter multislice spiral computed tomography. *Circulation.* 2002;106(16):2051-2054.
3. Mollet NR, Cademartiri F, Nieman K, et al. Multislice spiral computed tomography coronary angiography in patients with stable angina pectoris. *J Am Coll Cardiol.* 2004;43(12):2265-2270.
4. Leschka S, Alkadhi H, Plass A, et al. Accuracy of MSCT coronary angiography with 64-slice technology: first experience. *Eur Heart J.* 2005;26(15):1482-1487.
5. Hoffmann MH, Shi H, Schmitz BL, et al. Noninvasive coronary angiography with multislice computed tomography. *JAMA.* 2005;293(20):2471-2478.
6. Noto TJ Jr, Johnson LW, Krone R, et al. Cardiac catheterization 1990: a report of the Registry of the Society for Cardiac Angiography and Interventions (SCA&I). *Cathet Cardiovasc Diagn.* 1991;24(2):75-83.
7. Scanlon PJ, Faxon DP, Audet AM, et al. ACC/AHA guidelines for coronary angiography: a report of the American College of Cardiology/American Heart Association Task Force on practice guidelines (Committee on Coronary Angiography): developed in collaboration with the Society for Cardiac Angiography and Interventions. *J Am Coll Cardiol.* 1999;33(6):1756-1824.
8. Agatston AS, Janowitz WR, Hildner FJ, Zusmer NR, Viamonte M Jr, Detrano R. Quantification of coronary artery calcium using ultrafast computed tomography. *J Am Coll Cardiol.* 1990;15(4):827-832.
9. Gilard M, Cornily JC, Pennec PY, et al. Accuracy of multislice computed tomography in the preoperative assessment of coronary disease in patients with aortic valve stenosis. *J Am Coll Cardiol.* 2006;47(10):2020-2024.
10. Ropers D, Baum U, Pohle K, et al. Detection of coronary artery stenoses with thin-slice multi-detector row spiral computed tomography and multiplanar reconstruction. *Circulation.* 2003;107(5):664-666.
11. Hoffmann U, Moselewski F, Cury RC, et al. Predictive value of 16-slice multidetector spiral computed tomography to detect significant obstructive coronary artery disease in patients at high risk for coronary artery disease: patient- versus segment-based analysis. *Circulation.* 2004;110(17):2638-2643.
12. Kuettner A, Beck T, Drosch T, et al. Diagnostic accuracy of noninvasive coronary imaging using 16-detector slice spiral computed tomography with 188 ms temporal resolution. *J Am Coll Cardiol.* 2005;45(1):123-127.
13. Mollet NR, Cademartiri F, Krestin GP, et al. Improved diagnostic accuracy with 16-row multi-slice computed tomography coronary angiography. *J Am Coll Cardiol.* 2005;45(1):128-132.
14. Schuijff JD, Bax JJ, Shaw LJ, et al. Meta-analysis of comparative diagnostic performance of magnetic resonance imaging and multislice computed tomography for noninvasive coronary angiography. *Am Heart J.* 2006;151(2):404-411.
15. Schuijff JD, Pundziute G, Jukema JW, et al. Diagnostic accuracy of 64-slice multislice computed tomography in the noninvasive evaluation of significant coronary artery disease. *Am J Cardiol.* 2006;98(2):145-148.
16. Mollet NR, Cademartiri F, van Mieghem CA, et al. High-resolution spiral computed tomography coronary angiography in patients referred for diagnostic conventional coronary angiography. *Circulation.* 2005;112(15):2318-2323.
17. Shaw LJ, Iskandrian AE. Prognostic value of gated myocardial perfusion SPECT. *J Nucl Cardiol.* 2004;11(2):171-185.
18. Metz LD, Beattie M, Hom R, Redberg RF, Grady D, Fleischmann KE. The prognostic value of normal exercise myocardial perfusion imaging and exercise echocardiography: a meta-analysis. *J Am Coll Cardiol.* 2007;49(2):227-237.
19. Lichtlen PR, Bargheer K, Wenzlaff P. Long-term prognosis of patients with anginalike chest pain and normal coronary angiographic findings. *J Am Coll Cardiol.* 1995;25(5):1013-1018.
20. Pundziute G, Schuijff JD, Jukema JW, et al. Prognostic value of multislice computed tomography coronary angiography in patients with known or suspected coronary artery disease. *J Am Coll Cardiol.* 2007;49(1):62-70.